



**MonaLisa Touch®
International Scientific
Community Recognition**

Collection of Peer-Reviewed Scientific Papers

December 2022

MonaLisa Touch®

Index

- 1. A 12-week treatment with fractional CO₂ laser for vulvovaginal atrophy: a pilot study.**
Salvatore S. et al. *Climacteric*. 2014 Aug; 17(4):363-9. Epub 2014 Jun 5.
- 2. Microablative fractional CO₂ laser improves dyspareunia related to vulvovaginal atrophy: a pilot study.**
Salvatore S. et al. *Journal of Endometriosis and Pelvic Pain Disorders*. 2014; 6(3):150-6. Epub 2014 Jun 20.
- 3. Microscopic and ultrastructural modifications of postmenopausal atrophic vaginal mucosa after fractional carbon dioxide.**
Zerbinati N. et al. *Lasers in Medical Science*. 2015 Jan; 30(1):429-36. Epub 2014 Nov 20.
- 4. Sexual function after fractional microablative CO₂ laser in women with vulvovaginal atrophy.**
Salvatore S. et al. *Climacteric*. 2015 Apr; 18(2):219-25. Epub 2014 Dec 16.
- 5. Vulvo-vaginal atrophy: a new treatment modality using thermos-ablative fractional CO₂ laser.**
Perino A. et al. *Maturitas*. 2015 Mar; 80(3):296-301. Epub 2014 Dec 25.
- 6. Histological study on the effects of microablative fractional CO₂ laser on atrophic vaginal tissue: an ex vivo study.**
Salvatore S. et al. *Menopause*. 2015 Aug; 22(8):845-9.
- 7. The use of pulsed CO₂ laser for the treatment of vulvovaginal atrophy.**
Salvatore S. et al. *Current Opinion in Obstetrics and Gynecology*. 2015 Dic; 27(6):504-8.
- 8. Fractional CO₂ laser for vulvovaginal atrophy (VVA) dyspareunia relief in breast cancer survivors.**
Pieralli A. et al. *Archives of Gynecology and Obstetrics*. 2016 Oct; 294(4): 841-6. Epub 2016 May 12.
- 9. Is vaginal fractional CO₂ laser treatment effective in improving overactive bladder symptoms in post-menopausal patients? Preliminary results.**
Perino A. et al. *Eur Rev Med Pharmacol Sci*. 2016 Jun; 20(12):2491-7.
- 10. Fractional CO₂ Laser for Vulvovaginal Atrophy.**
Leksukulchai O et al. *Journal of the Medical Association of Thailand* Vol.99, No.7; Epub 2016 July.
- 11. The curative effect and feasibility analysis of fractional CO₂ laser in the treatment of vulvovaginal in postmenopausal women.**
Miao Y. et al. *Chin J Clin Obstet Gynecol*. 2016 July; 17(4):294-7.
- 12. The application of fractional CO₂ laser in the treatment of vulvar lichen sclerosus.**
Li J. et al. *Chin J Clin Obstet Gynecol*. 2016 July; 17(4):298-301.
- 13. The effect of microablative fractional CO₂ laser on vaginal flora of postmenopausal women.**
Athanasios S. et al. *Climacteric*. 2016 Oct; 19(5):512-8. Epub 2016 Aug 24.
- 14. An assessment of the safety and efficacy of a fractional CO₂ laser system for the treatment of vulvovaginal atrophy.**
Sokol E.R. et al. *Menopause*. 2016 Oct; 23(10):1102-7.

Index

15. **Fractional microablative CO₂ laser for vulvovaginal atrophy in women treated with chemotherapy and/or hormonal therapy for breast cancer: a retrospective study.**
Pagano T. et al. *Menopause*. 2016 Oct; 23(10):1108-13.
16. **Microablative fractional CO₂-laser therapy and the genitourinary syndrome of menopause: an observational study.**
Pitsouni E. et al. *Maturitas*. 2016 Dec; 94:131-6. Epub 2016 Sep 16.
17. **Fractional CO₂ laser treatment of the vestibule for patients with vestibulodynia and genitourinary syndrome of menopause: a pilot study.**
Murina F. et al. *J Sex Med*. 2016 Dec; 13(12):1915-7. Epub 2016 Nov 15.
18. **Fractional CO₂ laser treatment for vaginal atrophy and vulvar lichen sclerosis.**
Baggish M. S. *Journal of Gynecologic Surgery*. 2016 Dec; 32(6): 309-17. Epub 2016, Nov 21.
19. **Fractional CO₂ laser treatment: a novel approach for stress urinary incontinence management in post-menopausal women.**
González Isaza P. et al. *Urología Colombiana* 2017; 26(1). Epub 2016 Oct 09.
20. **Fractional CO₂ laser: from skin rejuvenation to vulvo-vaginal reshaping.**
Filippini M. et al. *Photomed Laser Surg*. 2017; 35(3):171-5. Epub 2016 Dec 30.
21. **Use of a novel fractional CO₂ laser for the treatment of genitourinary syndrome of menopause: 1-year outcomes.**
Sokol E.R. et al. *Menopause*. 2017 Jul; 24(7):810-814. Epub 2017 Feb 6.
22. **Safety and long-term efficacy of fractional CO₂ laser treatment in women suffering from genitourinary syndrome of menopause.**
Behnia-Willison F. et al. *Eur J Obstet Gynecol Reprod Biol*. June 2017; 213:39-44. Epub 2017 Apr 2.
23. **Fractional CO₂ laser therapy: a new challenge for vulvovaginal atrophy in postmenopausal women.**
Siliquini G.P. et al. *Climacteric*. 2017 Aug; 20(4):379-384. Epub 2017 May 15.
24. **Long-term effect of thermoablative fractional CO₂ laser treatment as a novel approach to urinary incontinence management in women with genitourinary syndrome of menopause.**
González Isaza P. et al. *Int Urogynecol J*. 2018 Feb;29(2):211-215. Epub 2017 May 18.
25. **Laser therapy for the genitourinary syndrome of menopause. A systematic review and meta-analysis.**
Pitsouni E. et al. *Maturitas*. 2017 Sep; 103:78-88. Epub 2017 Jun 27.
26. **CO₂-laser for the genitourinary syndrome of menopause. How many laser sessions?**
Athanasίου S. et al. *Maturitas*. 2017 Oct; 104:24-8. Epub 2017 Jul 21.
27. **Lasers for pelvic floor dysfunctions: is there evidence?**
Lang P. et al. *Curr Opin Obstet Gynecol*. Epub 2017 Jul 29.
28. **Randomized, double-blind, placebo-controlled clinical trial for evaluating the efficacy of fractional CO₂ laser compared with topical estriol in the treatment of vaginal atrophy in postmenopausal women.**
Cruz V.L. et al. *Menopause*. 2018 Jan; 25(1):21-28. Epub 2017 Jul 31.

Index

29. **Microablative fractional CO₂ laser for the genitourinary syndrome of menopause: power of 30 or 40 W?**
Pitsouni E. et al. *Lasers Med Sci*. 2017 Nov; 32(8):1865-1872. Epub 2017 Aug 2.
30. **Sexual function in women suffering from genitourinary syndrome of menopause treated with fractionated CO₂ laser.**
Salvatore S. et al. *Sex Med Rev*. 2017 Oct; 5(4):486-494. Epub 2017 Aug 23.
31. **Long-term reliability of fractionated CO₂ laser as a treatment for vulvovaginal atrophy (VVA) symptoms.**
Pieralli A. et al. *Arch Gynecol Obstet*. 2017 Nov; 296(5):973-978. Epub 2017 Sep 2.
32. **Fractional CO₂ laser of the vagina for genitourinary syndrome of menopause: Is the out-of-pocket cost worth the outcome of treatment?**
Lang P. et al. *Lasers Surg Med*. 2017 Dec; 49(10):882-885. Epub 2017 Sep 7.
33. **Fractional microablative CO₂ laser in breast cancer survivors affected by iatrogenic vulvovaginal atrophy after failure of nonestrogenic local treatments: a retrospective study.**
Pagano T. et al. *Menopause*. 2018 Jun; 25(6):657-662. Epub 2017 Nov 21.
34. **Early regenerative modifications of human postmenopausal atrophic vaginal mucosa following fractional CO₂ laser treatment.**
Salvatore S. et al. *Open Access Maced J Med Sci*. 2018 Jan 19; 6(1):6-14. Epub 2018 Jan 25.
35. **Fractional CO₂ laser for genitourinary syndrome of menopause in breast cancer survivors: clinical, immunological, and microbiological aspects.**
Becorpi A. et al. *Lasers Med Sci*. 2018 Jul; 33(5):1047-1054. Epub 2018 Mar 1.
36. **Response to letter to editor.**
Sokol ER. et al. *Menopause*. 2018; 25(2):243-4.
37. **The effects of fractional microablative CO₂ laser therapy on sexual function in postmenopausal women and women with a history of breast cancer treated with endocrine therapy.**
Gittens P. et al. *J Cosmet Laser Ther*. 2019 ;21(3):127-131. Epub 2018 Jun 8.
38. **CO₂ LASER for the treatment of vaginal symptoms of genitourinary syndrome of menopause.**
Jardin I. et al. *Gynecol Obstet Fertil Senol*. 2018 Nov; 46(10-11):729-734. Epub 2018 Sep 18.
39. **Microablative fractional CO₂ laser for the genitourinary syndrome of menopause: up to 12-month results.**
Athanasiou S. et al. *Menopause*. 2019 Mar;26(3):248-255. Epub 2018 Sep 24.
40. **How I do? A treatment with fractional CO₂ LASER for vulvovaginal atrophy symptoms in menopausal women.**
Jardin I. et al. *Gynecol Obstet Fertil Senol*. 2018 Nov;46(10-11):735-739. Epub 2018 Sep 25.
41. **Fractional CO₂ laser for treatment of stress urinary incontinence.**
Behnia-Willison F et al. *Eur J Obstet Gynecol Reprod Biol X*. Epub 2019 Jan 11.
42. **Efficacy of fractional CO₂ laser in the treatment of genitourinary syndrome of menopause in Latin-American population: first Peruvian experience.**
Tovar-Huamani J. et al. *Lasers Surg Med*. 2019 Aug; 51(6):509-515. Epub 2019 Feb 19.

Index

43. **In response to the FDA warning about the use of photomedicine in gynecology.**
Escribano J.J. et al. *Lasers Med Sci*. Epub 2019 Mar 4.
44. **Letter to the editor.**
Karram M. et al. *Menopause*. 2019; 26(6):688. Epub 2019 Apr 15.
45. **Case report: treatment for rectovaginal fistula in Crohn's disease using fractionate CO₂ vaginal laser with anti-TNF therapy.**
Drumond D.G. et al. *Photobiomodul Photomed Laser Surg*. 2019 Jul; 37(7):451-454. Epub 2019 Jun 17.
46. **Postpartum perineal pain: may the vaginal treatment with CO₂ laser play a key-role in this challenging issue?**
Filippini M. et al. *J Matern Fetal Neonatal Med*. Epub 2019 Jun 17.
47. **The effect of fractional CO₂ laser treatment on the symptoms of pelvic floor dysfunctions: Pelvic Floor Distress Inventory-20 Questionnaire.**
Sipos A.G. et al. *Lasers Surg Med*. Epub 2019 Jun 25.
48. **Fractional CO₂ laser versus promestriene and lubricant in genitourinary syndrome of menopause: a randomized clinical trial.**
Politano C.A. et al. *Menopause*. 2019 Aug; 26(8):833-840.
49. **Vaginal CO₂ laser for the treatment of vulvovaginal atrophy in women with breast cancer: LAAVA pilot study.**
Pearson A. et al. *Breast Cancer Res Treat*. 2019 Nov; 178(1):135-140. Epub 2019 Aug 3.
50. **Intravaginal energy-based devices and sexual health of female cancer survivors: a systematic review and meta-analysis.**
Athanasίου S. et al. *Lasers Med Sci*. Epub 2019 Aug 8.
51. **LASER users' expert opinion in response to "The clinical role of LASER for vulvar and vaginal treatments in gynecology and female urology: An ICS/ISSVD best practice consensus document".**
Salvatore S. et al. *Neurourol Urodyn*. Epub 2019 Aug 20.
52. **A randomized clinical trial comparing vaginal laser therapy to vaginal estrogen therapy in women with genitourinary syndrome of menopause: The VeLVET Trial.**
Paraiso M.F.R. et al. *Menopause*. Epub 2019 Sep 30.
53. **Short-term efficacy of vaginal CO₂ laser therapy as a treatment modality for genitourinary syndrome of menopause.**
Kozma B. et al. *Orv Hetil*. 2019 Oct; 160(41):1617-1622.
54. **Ospemifene plus fractional CO₂ laser: a powerful strategy to treat postmenopausal vulvar pain.**
Murina F et al. *Gynecol Endocrinol*. Epub 2019 Oct 22.
55. **Promising impact of platelet rich plasma and carbon dioxide laser for stress urinary incontinence.**
Behnia-Willison F. et al. *Eur J Obstet Gynecol Reprod Biol X*. Epub 2019 Oct 22.
56. **Efficacy of fractional CO₂ laser treatment in postmenopausal women with genitourinary syndrome: a multicenter study.**
Filippini M. et al. *Menopause*. Epub 2019 Nov 25.

Index

- 57. Fractional CO₂ laser therapy for genitourinary syndrome of menopause for breast cancer survivors.**
Quick A.M. et al. *Support Care Cancer*. Epub 2019 Dec 6.
- 58. The effect of vaginal microablative fractional CO₂ laser treatment on vaginal cytology.**
Takacs P. et al. *Lasers Surg Med*. Epub 2020 Jan 9.
- 59. Effect of rescue fractional microablative CO₂ laser on symptoms and sexual dysfunction in women affected by vulvar lichen sclerosus resistant to long-term use of topic corticosteroid: a prospective longitudinal study.**
Pagano T. et al. *Menopause*. Epub 2020 Jan 13.
- 60. Efficacy of fractional CO₂ laser, promestriene, and vaginal lubricant in the treatment of urinary symptoms in postmenopausal women: a randomized clinical trial.**
Aguiar L.B. et al. *Lasers Surg Med*. Epub 2020 Jan 28.
- 61. Response letter to comments related to "The effect of microablative fractional CO₂ laser on vaginal flora of postmenopausal women".**
Athanasious S. et al. *Neurourology and Urodynamics*. Epub 2020 Feb 14.
- 62. Fractionated CO₂ Laser as Therapy in Recalcitrant Lichen Sclerosus.**
Balchander D. et al. *J Low Genit Tract Dis*. Epub 2020 Feb 14.
- 63. Effectiveness of CO₂ laser on urogenital syndrome in women with a previous gynecological neoplasia: a multicentric study.**
Angioli R. et al. *Int J Gynecol Cancer*. Epub 2020 Mar 27.
- 64. Fractional CO₂ Laser for Treatment of Vulvovaginal Atrophy: A Short Time Follow-up.**
Zinat Ghanbari et al. *Journal of Family and Reproductive Health* 2020 Jun.
- 65. A cost-effectiveness analysis of vaginal carbon dioxide laser therapy compared with standard medical therapies for genitourinary syndrome of menopause-associated dyspareunia.**
Wallace S.L. et al. *Am J Obstet Gynecol*. Epub 2020 Jun 17.
- 66. The effect of the CO₂ fractional laser or premarin vaginal cream on improving sexual function in menopausal women: a randomized controlled trial.**
Eftekhar T. et al. *Lasers Med Sci*. Epub 2020 Jun 21.
- 67. Fractional microablative CO₂ laser-related histological changes on vulvar tissue in patients with genitourinary syndrome of menopause.**
Pagano T. et al. *Lasers Surg Med*. Epub 2020 Aug 14.
- 68. Treatment for vaginal atrophy using microablative fractional CO₂ laser: a randomized double-blinded sham-controlled trial.**
Ruanphoo P. et al. *Menopause*. Vol.27, No.8, 2020.
- 69. CO₂ laser and the genitourinary syndrome of menopause: a randomized sham-controlled trial.**
Salvatore S. et al. *Climacteric*. Epub 2020 Oct 22.
- 70. Evaluation of the efficacy of fractional CO₂ laser in the treatment of vulvar and vaginal menopausal symptoms.**
Sindou-Faurie T. et al. *Arch Gynecol Obstet*. Epub 2020 Nov 11.

Index

- 71. The Fractional CO₂ Laser for the Treatment of Genitourinary Syndrome of Menopause: A Prospective Multicenter Cohort Study.**
Jingran Li et al. *Lasers in Surgery and Medicine* Epub 2020 Nov 19.
- 72. The beneficial effects of fractional CO₂ laser treatment on perineal changes during puerperium and breastfeeding period: a multicentric study.**
Luvero D. et al. *Lasers Med Sci.* Epub 2021 Jan 3.
- 73. The short-term efficacy and safety of fractional CO₂ laser therapy for vulvovaginal symptoms in menopause, breast cancer, and lichen sclerosus.**
Allysa N. Gardner et al. *Menopause* 28(5):511-516; Epub 2021 Jan 4.
- 74. Patient-reported sexual function of breast cancer survivors with genitourinary syndrome of menopause after fractional CO₂ laser therapy.**
Allison M. Quick et al. *Menopause* 28(6):642-649; Epub 2021 Feb 1.
- 75. Fractional CO₂ vaginal laser for the genitourinary syndrome of menopause in breast cancer survivors.**
Siliquini G.P. et al. *Breast Cancer Research and Treatment*; Epub 2021 Mar 16.
- 76. Comparison of topical fractional CO₂ laser and vaginal estrogen for the treatment of genitourinary syndrome in postmenopausal women: a randomized controlled trial.**
Paula Fernanda Santos Pallone Dutra et al. *Menopause* 28(7):756-763; Epub 2021 May 17.
- 77. Clobetasol Compared With Fractionated Carbon Dioxide Laser for Lichen Sclerosus: A Randomized Controlled Trial.**
Linda S Burkett et al. *Obstetrics and Gynecology* 137(6):968-978; Epub 2021 Jun 1.
- 78. Fractional CO₂ laser treatment effect on cervicovaginal lavage zinc and copper levels: a prospective cohort study.**
Sipos A.G. et al. *BMC Women's Health*; Epub 2021 Jun 6.
- 79. Conservative Management of Urinary Stress Incontinence in Selected Post Menopause Patients with Fractional CO₂ Laser.**
Juan Manuel Tovar et al. *Pakistan Journal of Medical & Health Sciences*, Vol.15, No.8, Epub 2021 Aug.
- 80. Treatment of Rectovaginal Fistula Using Fractionate CO₂ Vaginal Laser: A Case Series.**
Denise Gasparetti Drumond et al. *Photobiomodulation, Photomedicine, and Laser Surgery* Vol 39, Issue 9, Epub 2021 Sept 21.
- 81. Treatment of Vulvovaginal Atrophy with Fractional CO₂ Laser: Evaluating Real-World Data.**
Matthias Kiesel et al. *Photobiomodulation, Photomedicine, and Laser Surgery* Vol.39, Issue 11, Epub 2021 Nov 10.
- 82. Effects of fractional CO₂ laser treatment on patients affected by vulvar lichen sclerosus: a prospective study.**
M. Filippini et al. *Photobiomodulation, Photomedicine, and Laser Surgery* Vol 39, Issue 12, Epub 2021 Dec 8.
- 83. Long-Term Follow-Up of Fractional CO₂ Laser Therapy for Genitourinary Syndrome of Menopause in Breast Cancer Survivors.**
Allison M Quick et al. *Journal of Clinical Medicine* 11(3):774; Epub 2022 Jan 31.

Index

84. **CO₂-Laser therapy and Genitourinary Syndrome of Menopause: A Systematic Review and Meta-Analysis.**
M. Filippini et al. *The Journal of Sexual Medicine* 19(3):452-470; Epub 2022 Jan 29.
85. **Fractional CO₂ laser for vulvo-vaginal atrophy in gynecologic cancer patients: A valid therapeutic choice? A systematic review.**
D'Oria O et al. *European Journal of Obstetrics & Gynecology and Reproductive Biology*; Epub 2022 Aug 24.
86. **Comparison of Severity of Genitourinary Syndrome of Menopause Symptoms After Carbon Dioxide Laser vs Vaginal Estrogen Therapy: A Systematic Review and Meta-analysis.**
Y. Jang et al. *JAMA Netw Open* 19(3):452-470; 5(9):e2232563; Epub 2022 Sep 21.

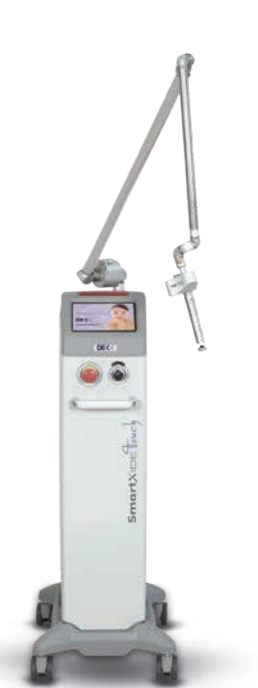MonaLisa Touch[®]

Performed only by DEKA systems

SmartXide²



SmartXide Touch



Glide



Editorial

After over 10 years, I'm more convinced than ever in the incredible therapeutic capacity of the MonaLisa Touch® laser technology, which has proven to be an effective mini-invasive method with high safety rates and minimal post-treatment downtime.

This revolutionary procedure has been the subject of various scientific publications lately and has achieved confirmation by a broad scientific community internationally.

Many studies have objectively and subjectively testified to the significant quality of life improvement by patients with genitourinary syndrome of menopause. These results are even more significant considering the replicability of the improvement of the symptoms of vaginal atrophy, urinary symptoms and sexual dysfunction reported in publications from all over the globe, even in randomised studies. Other projects are now underway and may soon introduce new indications for this therapeutic modality.

Prof. Stefano Salvatore

Associate professor of Gynaecology and Obstetrics
Director of the Urogynaecology Unit
IRCCS Ospedale S. Raffaele of Milan
President of the Italian Association of Urogynaecology
Former President of the European Association of Urogynaecology

Scientifically and clinically proving the high safety and efficacy levels of the MonaLisa Touch® therapy is the foundation of the journey we started in 2009 and which continue carrying forward.

In 2020 DEKA INSTITUTED the ETHICS COMMITTEE FOR WOMEN'S INTIMATE HEALTH (Medical Advisory Board - MAB).

The committee will contribute to defining a clinical development plan inclusive of new protocols for women's intimate health.

I am honoured to be the coordinator of MAB, the Medical Advisory Board, where nearly all continents are represented.

To conclude, I thank my team, without whose contribution it would not have been possible to produce the data published up to now regarding MonaLisa Touch® and the Medical Advisory Board that is a milestone for the scientific community and the wellness of women's intimate health.



A 12-week treatment with fractional CO₂ laser for vulvovaginal atrophy: A pilot study

Salvatore S¹, Nappi RE², Zerbini N³, Calligaro A⁴, Ferrero S⁵,
Origoni M¹, Candiani M¹, Leone Roberti Maggiore U¹

1: San Raffaele Hospital, Milan - Italy; 2: Policlinico S. Matteo, University of Pavia, Pavia - Italy;
3: University of Insubria, Varese - Italy; 4: University of Pavia, Pavia - Italy; 5: San Martino Hospital, University of Genoa, Genoa - Italy.



Abstract

Objective

This pilot study aimed to assess the efficacy and feasibility of fractional CO₂ laser in the treatment of vulvovaginal atrophy (VVA) in postmenopausal women.

Methods

VVA symptoms were assessed before and after three applications of laser over 12 weeks in 50 women (age 59.6 ± 5.8 years) dissatisfied with previous local estrogen therapies. Subjective (visual analog scale) and objective (Vaginal Health Index Score, VHIS) measures were used during the study period to assess VVA. Quality of life was measured by using the SF-12. A subjective scale to evaluate the degree of pain related to the laser application and the degree of difficulty to perform the laser procedure was used.

Results

Fractional CO₂ laser treatment was effective to improve VVA symptoms (vaginal dryness, vaginal burning, vaginal itching, dyspareunia, dysuria; $p < 0.001$) at 12-week follow-up, as well as the VHIS (13.1 ± 2.5 at baseline vs. 23.1 ± 1.9; $p < 0.001$). Both physical and mental scores of quality of life were significantly improved in comparison with baseline ($p < 0.001$). Satisfaction with the laser procedure was reported by 42 women (84%) and a minimal discomfort was experienced at the first laser application, mainly because of the insertion and the movements of the probe. Finally, the technique was very easy to perform in all women starting from the second application at week 4 and no adverse events were recorded during the study period.

Conclusions

A 12-week treatment with the fractional CO₂ laser was feasible and induced a significant improvement of VVA symptoms by ameliorating vaginal health in postmenopausal women. Further controlled studies should be performed to confirm the present data and to assess the long-term effects of the laser procedure on vaginal tissues.

Microablative fractional CO₂ laser improves dyspareunia related to vulvovaginal atrophy: A pilot study

Salvatore S¹, Leone Roberti Maggiore U¹, Origoni M¹, Parma M¹, Quaranta L¹, Sileo F¹, Cola A¹, Bainsi I¹, Ferrero S², Candiani M¹, Zerbini N³

1: San Raffaele Hospital, Milan – Italy. 2: San Martino Hospital, University of Genoa, Genoa – Italy. 3: University of Insubria, Varese – Italy.



Abstract

This pilot study aimed to assess the efficacy in treating sexually active menopausal patients who had dyspareunia related to vulvovaginal atrophy (VVA).

The intensity of VVA symptoms was recorded for each patient. Patients were administered the Short Form 12 (SF-12) and the female sexual function index (FSFI) to assess quality of life and sexual function, respectively. An objective evaluation of female urogenital health was performed using the Gloria Bachman Vaginal Health Index (VHI).

At 12-week follow-up, the laser treatment was efficacious in improving dyspareunia in 100% of patients included in the study ($n = 15$). The intensity of dyspareunia significantly decreased from baseline (8.7 ± 1.0) to 12-week follow-up (2.2 ± 1.0 ; $p < 0.001$). In addition, all other VVA symptoms significantly ameliorated at the same follow-up. Furthermore, after the treatment, a significant improvement in quality of life (QoL) and sexual function were shown.

This pilot study demonstrated that treatment with the microablative fractional CO₂ laser of patients with dyspareunia related to VVA was efficacious at 12-week follow-up.

Microscopic and ultrastructural modifications of postmenopausal atrophic vaginal mucosa after fractional carbon dioxide laser treatment

Zerbinati N¹, Serati M¹, Origoni M², Candiani M², Iannitti T³,
Salvatore S², Marotta F⁴, Calligaro A⁵

1: University of Insubria, Varese – Italy. 2: San Raffaele Hospital, Milan – Italy. 3: University of Leeds, Leeds – United Kingdom.
4: ReGenera Research Group for Aging Intervention, Milan – Italy. 5: University of Pavia, Pavia – Italy.



Abstract

Vaginal atrophy occurring during menopause is closely related to the dramatic decrease in ovarian estrogens due to the loss of follicular activity.

Particularly, significant changes occur in the structure of the vaginal mucosa, with consequent impairment of many physiological functions. In this study, carried out on bioptic vaginal mucosa samples from postmenopausal, nonestrogenized women, we present microscopic and ultrastructural modifications of vaginal mucosa following fractional carbon dioxide (CO₂) laser treatment. We observed the restoration of the vaginal thick squamous stratified epithelium with a significant storage of glycogen in the epithelial cells and a high degree of glycogen-rich shedding cells at the epithelial surface.

Moreover, in the connective tissue constituting the lamina propria, active fibroblasts synthesized new components of the extracellular matrix including collagen and ground substance (extrafibrillar matrix) molecules.

Differently from atrophic mucosa, newly-formed papillae of connective tissue indented in the epithelium and typical blood capillaries penetrating inside the papillae, were also observed. Our morphological findings support the effectiveness of fractional CO₂ laser application for the restoration of vaginal mucosa structure and related physiological trophism. These findings clearly coupled with striking clinical relief from symptoms suffered by the patients before treatment remodeling of vaginal connective tissue without causing damage to surrounding tissue.

Sexual function after fractional microablative CO₂ laser in women with vulvovaginal atrophy

Salvatore S¹, Nappi RE², Parma M¹, Chionna R¹, Lagona F¹, Zerbinati N³, Ferrero S⁴, Origoni M¹, Candiani M¹, Leone Roberti Maggiore U¹

1: San Raffaele Hospital, Milan – Italy. 2: Policlinico S. Matteo, University of Pavia, Pavia – Italy. 3: University of Insubria, Varese – Italy. 4: San Martino Hospital, University of Genoa, Genoa, Italy.



Abstract

Objective

To investigate the effects of fractional microablative CO₂ laser on sexual function and overall satisfaction with sexual life in postmenopausal women with vulvovaginal atrophy (VVA).

Method

This prospective study included 77 postmenopausal women (mean age 60.6 ± 6.2 years) treated for VVA symptoms with the fractional microablative CO₂ laser system (SmartXide² V²LR, MonaLisa Touch[®], DEKA, Florence, Italy). Sexual function and quality of life were evaluated with the Female Sexual Function Index (FSFI) and the Short Form 12 (SF-12), respectively, both at baseline and at 12-week follow-up. A 10-mm visual analog scale was used to measure the overall satisfaction with sexual life and the intensity of VVA symptoms (vaginal burning, vaginal itching, vaginal dryness, dyspareunia and dysuria) before and after the study period.

Results

We observed a significant improvement in the total score and the scores in each specific domain of the FSFI at 12-week follow-up compared to baseline ($p < 0.001$). After concluding the laser treatment, the overall satisfaction with sexual life significantly improved ($p < 0.001$). Seventeen (85%) out of 20 (26%) women, not sexually active because of VVA severity at baseline, regained a normal sexual life at the 12-week follow-up. Finally, we also found a significant improvement in each VVA symptom ($p < 0.001$) and in quality-of-life evaluation, both for the scores in the physical ($p = 0.013$) and mental ($p = 0.002$) domains.

Conclusions

Fractional microablative CO₂ laser treatment is associated with a significant improvement of sexual function and satisfaction with sexual life in postmenopausal women with VVA symptoms.

Vulvo-vaginal atrophy: A new treatment modality using thermo-ablative fractional CO₂ laser

Perino A¹, Calligaro A², Forlani F¹, Tiberio C¹, Cucinella G¹,
Svelato A¹, Saitta S³, Calagna G¹

1: University Hospital "P. Giaccone", Palermo – Italy. 2: University of Pavia, Pavia – Italy.
3: University of Messina, Messina – Italy.



Abstract

Objective

To evaluate the efficacy and feasibility of thermo-ablative fractional CO₂ laser for the treatment of symptoms related to vulvo-vaginal atrophy (VVA) in post-menopausal women.

Methods

From April 2013 to December 2013, post-menopausal patients who complained of one or more VVA-related symptoms and who underwent vaginal treatment with fractional CO₂ laser were enrolled in the study. At baseline (T0) and 30 days post-treatment (T1), vaginal status of the women was evaluated using the Vaginal Health Index (VHI), and subjective intensity of VVA symptoms was evaluated using a visual analog scale (VAS). At T1, treatment satisfaction was evaluated using a 5-point Likert scale.

Results

During the study period, a total of 48 patients were enrolled. Data indicated a significant improvement in VVA symptoms (vaginal dryness, burning, itching and dyspareunia) ($P < 0.0001$) in patients who had undergone 3 sessions of vaginal fractional CO₂ laser treatment. Moreover, VHI scores were significantly higher at T1 ($P < 0.0001$). Overall, 91.7% of patients were satisfied or very satisfied with the procedure and experienced considerable improvement in quality of life (QoL). No adverse events due to fractional CO₂ laser treatment occurred.

Conclusions

Thermo-ablative fractional CO₂ laser could be a safe, effective and feasible option for the treatment of VVA symptoms in post-menopausal women.

Histological study on the effects of microablative fractional CO₂ laser on atrophic vaginal tissue: An ex vivo study



Salvatore S¹, Leone Roberti Maggiore U¹, Athanasiou S², Origoni M¹,
Candiani M¹, Calligaro A³, Zerbinati N⁴

1: San Raffaele Hospital, Milan – Italy; 2: National and Kapodistrian University of Athens, Athens – Greece.
3: University of Pavia, Pavia – Italy; 4: University of Insubria, Varese – Italy.

Abstract

Objective

Microablative fractional CO₂ laser has been proven to determine tissue remodeling with neoformation of collagen and elastic fibers on atrophic skin. The aim of our study is to evaluate the effects of microablative fractional CO₂ laser on postmenopausal women with vulvovaginal atrophy using an ex vivo model.

Methods

This is a prospective ex vivo cohort trial. Consecutive postmenopausal women with vulvovaginal atrophy managed with pelvic organ prolapse surgical operation were enrolled. After fascial plication, the redundant vaginal edge on one side was treated with CO₂ laser (SmartXide²; DEKA Laser, Florence, Italy). Five different CO₂ laser setup protocols were tested. The contralateral part of the vaginal wall was always used as control. Excessive vagina was trimmed and sent for histological evaluation to compare treated and nontreated tissues. Microscopic and ultrastructural aspects of the collagenic and elastic components of the matrix were studied, and a specific image analysis with computerized morphometry was performed. We also considered the fine cytological aspects of connective tissue proper cells, particularly fibroblasts.

Results

During the study period, five women were enrolled, and 10 vaginal specimens were finally retrieved. Four different settings of CO₂ laser were compared. Protocols were tested twice each to confirm histological findings. Treatment protocols were compared according to histological findings, particularly in maximal depth and connective changes achieved. All procedures were uneventful for participants.

Conclusions

This study shows that microablative fractional CO₂ laser can produce a remodeling of vaginal connective tissue without causing damage to surrounding tissue.



Current Opinion in Obstetrics and Gynecology - Vol. 27, No. 6, 2015

The use of pulsed CO₂ lasers for the treatment of vulvovaginal atrophy

Salvatore S¹, Athanasiou S², Candiani M¹

1: San Raffaele Hospital, Milan – Italy. 2: National and Kapodistrian University of Athens, Athens – Greece.

Abstract

Purpose of Review

This article reviews the literature regarding the safety and efficacy of the use of a pulsed CO₂ laser for the treatment of vulvovaginal atrophy (VVA).

Recent Findings

Prospective observational studies have demonstrated histological changes after the use of pulsed CO₂ laser vaginally in atrophic conditions. Increased collagen and extracellular matrix production has been reported together with an increase in the thickness of the vaginal epithelium with the formation of new papilla. Three different observational studies reported a significant improvement of VVA assessed subjectively (with a 10-point visual analogue scale) and objectively (using the Vaginal Health Index) after a cycle of three

treatments of pulsed CO₂ laser. Also sexual function (assessed with the Female Sexual Function Index) and quality of life (evaluated with the SF12 questionnaire) significantly improved. No complications or sideeffects were reported during or after the laser procedure that was performed in an outpatient setting.

Summary

Increasing evidence with histological and clinical data supports the use of pulsed CO₂ lasers in the treatment of VVA; however, no randomized control trial (sham versus treatment) has yet been produced and no data on the duration of therapy are currently available.

Fractional CO₂ laser for vulvovaginal atrophy (VVA) dyspareunia relief in breast cancer survivors

Pieralli A¹, Fallani MG¹, Becorpi A¹, Bianchi C¹, Corioni S¹, Longinotti M¹, Tredici Z¹, Guaschino S¹

¹: Careggi University Hospital, Florence - Italy.



Abstract

Purpose

The aim of this study was to evaluate the efficacy of fractional CO₂ laser therapy in breast cancer survivors as a therapeutic method for vulvovaginal atrophy (VVA) dyspareunia.

Methods

50 patients (mean age 53.3 years) underwent fractional microablative CO₂ laser treatment for dyspareunia in oncological menopause (mean time of menopause 6.6 years). The Gloria Bachmann's Vaginal Health Index (VHI) score was chosen as system to evaluate the presence of VVA and its improvement after the treatment. Intensity of dyspareunia was evaluated using a visual analog scale (VAS).

Results

Data indicated a significant improvement in VVA dyspareunia ($p < 1.86e-22$) in breast cancer survivors who had undergone 3 sessions of vaginal fractional CO₂ laser treatment. Moreover, VHI scores were significantly higher 30 days post-treatment (T4) ($p < 0.0001$). 76 % of patients were satisfied or very satisfied with the treatment results. The majority (52 %) of patients were satisfied after a long-term follow-up (mean time 11 months). No adverse events due to fractional CO₂ laser treatment occurred.

Conclusions

The treatment with fractionated CO₂ laser appeared to be a feasible and effective treatment for VVA dyspareunia in breast cancer survivors with contraindications to hormonal treatments.

Is vaginal fractional CO₂ laser treatment effective in improving overactive bladder symptoms in post-menopausal patients? Preliminary results

Perino A¹, Cucinella G², Gugliotta G³, Saitta S⁴, Polito S⁵,
Adile B², Marci R⁵, Calagna G¹

1: University Hospital, Palermo – Italy. 2: Villa Sofia-Cervello Hospital, Palermo – Italy. 3: University of Messina, Messina – Italy.
4: "Barone I. Romeo" Hospital, Patti (ME) – Italy. 5: University of Ferrara, Ferrara – Italy.



Abstract

Objective

To evaluate the role of vaginal fractional CO₂ laser treatment in the relief of Overactive Bladder (OAB) symptoms in post-menopausal women.

Patients and Methods

Post-menopausal women who complained of one or more symptoms related to vulvo-vaginal atrophy (VVA), who experienced symptoms of OAB and who underwent vaginal treatment with fractional CO₂ laser were enrolled in the study. At baseline (T0) and 30 days post-treatment (T1), vaginal status (using Vaginal Health Index - VHI), subjective intensity of VVA symptoms (using a visual analog scale - VAS) and micturition diary were evaluated. OAB symptoms were also assessed using a validated questionnaire.

Results

Thirty patients were enrolled. A statistically significant improvement in VVA symptoms was observed and in VHI at T1 ($p < 0.0001$). A significant improvement was also identified in the micturition diary, in number of urge episodes and OAB-q ($p < 0.0001$). Nine of the 30 patients suffered from incontinence episodes and had improved at T1.

Conclusions

We showed that fractionated CO₂ laser vaginal treatment has proved to be effective in improving OAB symptoms in post-menopausal women. Moreover, it is a safe and efficacious measure for the relief of VVA related conditions. Further long-term studies are needed to confirm these preliminary results.

Journal of the Medical Association of Thailand - Vol. 99, No. 7, 2016 July

Fractional CO₂ Laser for Vulvovaginal Atrophy

Lekskulchai O, Mairaing K, Vinayanuvattikhun N

Thammasat University, Rangsit Campus, Pathum Thani - Thailand.



Abstract

Purpose

To evaluate the short term efficacy and safety of Fractional CO₂ laser for the treatment of vulvovaginal atrophy.

Methods

112 menopausal women were recruited. All women with VVA were treated by using Fractional CO₂ laser; power 30 W 1-3 stacks with 360° vaginal probe for 3 consecutive times, 4 weeks apart. Before laser treatment, the subjective measurement of VVA symptoms was evaluated by using a questionnaire and the objective measurements were evaluated by using pH paper and VMI. Visual analog pain-score was used to scaling their discomfort during and immediately after each treatment. At 3 months after the last procedure, the subjective and objective measurements were re-assessed. Any short-term and long-term adverse event recorded. Statistical analysis was performed by using SPSS program with p-value <0.05.

Results

There was a significant reduction of the VVA symptom score after laser treatment. The average percentage of pretreatment VMI was 34.7+16.1% and at one and three months after complete laser course, it was significantly increased with the mean change of 25.0+12.2% and 34.8+15.5%, respectively. For the vaginal pH, the average pH before treatment was 7.5+1.0 and the average decrement after 3 months was 0.9+1.3 with statistical significance, p-value <0.01. There were no serious complications and all were satisfied with the treatment.

Conclusions

Fractional CO₂ laser could ameliorate the VVA symptoms with at least 3 months of long lasting improvement of vaginal health with safety.

Chinese Journal of Clinical Obstetrics and Gynecology – Vol. 17, No. 4, 2016

The curative effect and feasibility analysis of fractional CO₂ laser in the treatment of vulvovaginal in postmenopausal women

Miao Y¹, Li J¹, Wang J¹

1: Peking University People's Hospital, Beijing – China.



Abstract

Objective

This prospective study aimed to assess the curative efficacy and feasibility of fractional CO₂ laser in the treatment of vulvo-vaginal atrophy (VVA) in postmenopausal women.

Methods

30 patients with VA recruited in this study, fractional CO₂ laser treatment was applied, visual analogue scale (VAS) and vaginal health index score (VHIS) measures were used to assess VVA, and degree of pain before and after the treatment, additionally, satisfaction survey was done post treatment.

Results

Fractional CO₂ laser treatment was significant improved VVA symptoms (vaginal itching, 6.00±2.60 vs. 1.38±0.97, P<0.001; vaginal dryness 7.04±2.26 vs. 1.88±1.03, P<0.001; vaginal burning, 6.25±2.13 vs. 1.50±0.88, P<0.001; dyspareunia, 7.54±2.54 vs. 2.04±1.15, P<0.001), as well as the VHIS (9.79±2.76 vs. 16.33±2.06, P<0.001). Satisfaction with the laser procedure was reported by 28 women (93.33%) and a minimal discomfort was experienced at the laser application. No adverse events were recorded.

Conclusions

The fractional CO₂ laser treatment can improve the VVA symptoms in postmenopausal patients with vulvo-vaginal atrophy and was proved to be a simple, outpatient therapy for VVA patients.

Chinese Journal of Clinical Obstetrics and Gynecology – Vol. 17, No. 4, 2016

The application of fractional CO₂ laser in the treatment of vulvar lichen sclerosis

Li J¹, Miao Y¹, Wang J¹

¹: Peking University People's Hospital, Beijing – China.



Abstract

Objectives

To investigate the efficacy and side effects for fractional CO₂ laser in the treatment of vulvar lichen sclerosis (VLS).

Methods

31 patients with VLS symptoms were enrolled prospectively from July 2015 to April 2016 in Peking University People's Hospital. The fractional CO₂ laser was used for VLS lesions, a total of 3-5 times, each time per-month. Visual analogue scale (VAS) was assessed the degree of vulvar pruritus, skin chapping, dyspareunia before and after treatment. After the treatment, satisfaction survey was done.

Results

The rate improvement of VLS symptoms was 90.32% (28/31) with fractional CO₂ laser ($P < 0.001$). Compare with before treatment, there were significant difference in pruritus score at the first and the third after treatment one month (8.07 ± 1.97 vs. 3.43 ± 0.94 and 1.93 ± 0.62 , $P < 0.001$), vulvar skin chapping score (3.5 ± 1.79 vs. 1.36 ± 1.22 and 0.64 ± 0.84 , $P < 0.005$), respectively. The dyspareunia score (4.29 ± 2.70 vs. 1.14 ± 0.95 , $P < 0.05$) were improved significantly at the third after treatment one month. After treatment 48h, there were 2 cases with mild pain, 6 cases with local mils hyperemia, 4 cases with mild swelling. No adverse events due to fractional CO₂ laser treatment occurred. During 3-7 months follow-up, 4 cases (12.9%) with the skin color from white to gray, 2 cases recovered sex from 6 cases. The overall satisfaction rate was 96.77% (30/31).

Conclusions

The fractional CO₂ laser is effective, minimal injury and acceptable side effects for vulvar lichen sclerosis, and may be a new treatment for it.

The effect of microablative fractional CO₂ laser on vaginal flora of postmenopausal women

Athanasίου S¹, Pitsouni E^{1,2}, Antonopoulou S³, Zacharakis D¹,
Salvatore S⁴, Falagas ME^{2,5,6}, Grigoriadis T⁷

1: National and Kapodistrian University of Athens, Athens – Greece. 2: AIBS, Athens – Greece.
3: “G. Gennimatas” General Hospital, Athens – Greece. 4: San Raffaele Hospital, Milan – Italy. 5: IASO General Hospital, Athens – Greece.
6: Tufts University School of Medicine, Boston, MA - USA. 7: “Alexandra Hospital”, Athens - Greece.



Abstract

Objectives

To assess the effect of microablative fractional CO₂ laser (MFCO₂-Laser) therapy on the vaginal microenvironment of postmenopausal women.

Methods

Three laser therapies at monthly intervals were applied in postmenopausal women with moderate to severe symptoms of genitourinary syndrome of menopause, pH of vaginal fluid >4.5 and superficial epithelial cells on vaginal smear <5%. Vaginal fluid pH values, fresh wet mount microscopy, Gram stain and aerobic and anaerobic cultures were evaluated at baseline and 1 month after each subsequent therapy. Nugent score and Hay-Ison criteria were used to evaluate vaginal flora.

Results

Fifty-three women (mean age 57.2 ± 5.4 years) participated and completed this study. MFCO₂-Laser therapy increased Lactobacillus (p < 0.001) and normal flora (p < 0.001) after the completion of the therapeutic protocol, which decreased vaginal pH from a mean of 5.5 ± 0.8 (initial value) to 4.7 ± 0.5 (p < 0.001). The prevalence of Lactobacillus changed from 30% initially to 79% after the last treatment. Clinical signs and symptoms of bacterial vaginosis, aerobic vaginitis or candidiasis did not appear in any participant.

Conclusions

MFCO₂-Laser therapy is a promising treatment for improving the vaginal health of postmenopausal women by helping repopulate the vagina with normally existing Lactobacillus species and reconstituting the normal flora to premenopausal status.

An assessment of the safety and efficacy of a fractional CO₂ laser system for the treatment of vulvovaginal atrophy

Sokol ER¹, Karram MM²

1: Stanford University, Stanford, CA - USA. 2: The Christ Hospital, Cincinnati, OH - USA.



Abstract

Objective

The aim of the study was to assess the safety and efficacy of a novel fractional CO₂ laser for the treatment of genitourinary syndrome of menopause (GSM).

Patients and Methods

Women presenting with GSM and meeting study criteria were enrolled. Examinations at baseline and follow-up (3 mo after final treatment) evaluated dilator tolerance and vaginal pH. Visual analog scales were used to assess pain, vaginal burning, vaginal itching, vaginal dryness, dyspareunia, and dysuria; Vaginal Health Index scores were completed before each treatment and at follow-up; Female Sexual Function Index and Short Form 12 questionnaires were also completed. Participant satisfaction was measured on a 5-point Likert scale (1=very dissatisfied, 5=very satisfied). Women received three laser treatments, 6 weeks apart.

Results

Thirty women participated (mean age 58.6±8.8 y). None withdrew or were discontinued due to an adverse event; three were lost to follow-up. Average improvement in visual analog scale scoring was 1.7±3.2 for pain, 1.4±2.9 for burning, 1.4±1.9 for itching, 6.1±2.7 for dryness, 5.1±3.0 for dyspareunia, and 1.0±2.4 for dysuria; improvement in average Vaginal Health Index and Female Sexual Function Index scores were statistically significant ($P<0.001$). Twenty-five of 30 participants (83%) showed increase in comfortable dilator size at 3-month follow up. Before the second and third treatments, 86.6% (26 of 30) of women reported they were better or much better than at the previous treatment; 26 of 27 women (96%) were reportedly satisfied or extremely satisfied at follow-up.

Conclusions

In this sample, the data suggest that the fractional CO₂ laser is effective and safe for treatment of the symptoms associated with GSM.

Fractional microablative CO₂ laser for vulvovaginal atrophy in women treated with chemotherapy and/or hormonal therapy for breast cancer: A retrospective study

Pagano T, De Rosa P, Vallone R, Schettini F, Arpino G, De Placido S, Nazzaro G, Locci M, De Placido G

University of Naples "Federico II", Naples - Italy.



Abstract

Objectives

Breast cancer is one of the most common malignancies in women. Hormonal treatment and chemotherapy induce a transient or permanent menopause status. Vulvovaginal atrophy (VVA) is a frequent debilitating symptom of menopause that is best treated with local or systemic estrogen formulations. Because estrogens drive the growth of the majority of breast cancers, most effective VVA therapies are precluded. The aim of this study was to evaluate the effects of fractional microablative CO₂ laser on sexual function and in relieving symptoms in women with breast cancer and VVA induced or exacerbated by iatrogenic menopause.

Methods

This retrospective study included 26 women affected by hormone-receptor positive breast tumors and treated for VVA symptoms with the fractional microablative CO₂ laser system. Every 30 to 40 days, women underwent a cycle of treatment for a total of three cycles. During each cycle, women underwent a gynecological examination and completed visual analog scale questionnaires designed to assess (1) the degree of symptoms and (2) procedure-related discomfort.

Results

Treatment resulted in a significant regression of VVA symptoms and procedure-related discomfort versus baseline ($P < 0.001$ in almost all cases). No adverse reactions were observed nor reported by women.

Conclusions

Fractional microablative CO₂ laser treatment is associated with a significant improvement of VVA symptoms in women affected by hormone-driven breast cancer. This procedure has the advantage of relieving iatrogenic/physiological VVA symptoms without resorting to contraindicated estrogen preparations, which have been the most effective therapy thus far.

Microablative fractional CO₂-laser therapy and the genitourinary syndrome of menopause: An observational study

Pitsouni E¹, Grigoriadis T¹, Tsiveleka A², Zacharakis D¹, Salvatore S³, Athanasiou S¹

1: National and Kapodistrian University of Athens, Athens - Greece.
2: "Alexandra Hospital", Athens - Greece. 3: San Raffaele Hospital, Milan - Italy.



Abstract

Objective

This study aimed to assess the effect of the Microablative Fractional CO₂ Laser (CO₂-laser) therapy on vaginal pathophysiology and the symptoms of the Genitourinary Syndrome of Menopause (GSM).

Methods

Postmenopausal women with moderate to severe symptoms of GSM underwent three sessions of CO₂-laser therapy at monthly intervals. Participants were evaluated at baseline and 4 weeks after the last treatment.

Main Outcome Measures

The primary outcomes were Vaginal Maturation Value (VMV) and Vaginal Health Index Score (VHIS). Secondary outcomes included symptoms of GSM, Female Sexual Function Index (FSFI), International Consultation on Incontinence Questionnaire of Female Urinary Tract Symptoms (ICIQ-FLUTS) and Urinary Incontinence Short Form (ICIQ-UI SF), Urogenital Distress Inventory (UDI-6) and King's Health Questionnaire (KHQ).

Results

Fifty-three postmenopausal women completed this study. VMV, VHIS and FSFI increased significantly. Dyspareunia, dryness, burning, itching, dysuria, frequency, urgency, urgency incontinence, stress incontinence and scores on the ICIQ-FLUTS, ICIQ-UI SF, UDI-6 and KHQ decreased significantly. Factors predicting for which women the CO₂-laser therapy was more effective were not identified.

Conclusion

This study suggests that intravaginal CO₂-laser therapy for postmenopausal women with clinical signs and symptoms of GSM may be effective in improving both vaginal pathophysiology and reported symptoms.

Fractional CO₂ laser treatment of the vestibule for patients with vestibulodynia and genitourinary syndrome of menopause: A pilot study

Murina F¹, Karram M², Salvatore S³, Felice R¹

1: V. Buzzi Hospital, Milan - Italy. 2: The Christ Hospital, Cincinnati, OH – USA.
3: San Raffaele Hospital, Milan – Italy.



Abstract

Introduction

Chronic vulvar pain and burning remains one of the most perplexing problems faced by practicing gynecologists.

Aim

To evaluate the effectiveness and safety of the application of micro-ablative fractional CO₂ laser to the vulvar vestibule in the management of patients with vulvar pain from vestibulodynia or genitourinary syndrome of menopause.

Methods

Patients (N=70) underwent fractional micro-ablative CO₂ laser treatment for vestibular pain plus vestibulodynia (n = 37) or genitourinary syndrome of menopause (n = 33). Inclusion criteria were the existence of vestibular atrophic changes and the absence of moderate or severe pelvic floor hypertonic dysfunction.

Main Outcome Measures

A visual analog scale of pain and the Marinoff score of dyspareunia were chosen to evaluate improvement. Grading of vestibular health also was quantified using a four-point scoring system (0 = no atrophy, 3 = severe atrophy). Data were collected at baseline, at weeks 4, 8, and 12, and 4 months after the final treatment.

Results

For visual analog scale and dyspareunia scoring and for the overall vestibular health index scoring, statistically significant improvement was noted after three sessions of vestibular fractional CO₂ laser treatment. Improvement gradually increased throughout the study period and was maintained through the 4-month follow-up visit. There was no statistically significant difference in outcomes between the two study groups. No adverse events from fractional CO₂ laser treatment were noted. Overall, 67.6% of patients stated significant improvement from the laser procedure.

Conclusion

This preliminary case series showed encouraging results using fractional CO₂ laser treatment of the vestibule in women with vestibulodynia and genitourinary syndrome of menopause.

Fractional CO₂ laser treatment for vaginal atrophy and vulvar lichen sclerosis

Baggish MS

University of California, San Francisco, CA – USA.



Abstract

Objectives

The aim of this research was to assess the efficacy of fractional CO₂ laser energy for treating vaginal atrophy and lichen sclerosis.

Materials and Methods

The first study population was 23 postmenopausal women diagnosed with vaginal atrophy via microscopic evaluation and who were symptomatic. The second study population was 27 postmenopausal women diagnosed with lichen sclerosis by biopsy and who were symptomatic. Patients with vaginal atrophy had 3 treatment sessions spaced at 4–6 weeks between each session. Laser settings for this group were: power: Watts, 30; time, 1000 microseconds; and spacing, 1000 micrometers. For the lichen sclerosis group, the power was set at 20 Watts and 3–4 treatments were given at 4–6-week intervals.

Results

In the vaginal atrophy cohort, 22/23 women who previously complained of dryness and discomfort had these symptoms alleviated and vaginal microscopic exam showed significant changes in color, elasticity, and wetness following 3 courses of CO₂ laser fractional treatment; additionally 20/23 women had elimination of urinary frequency and urgency, 18/21 women had alleviation of dyspareunia. In the lichen sclerosis cohort 24/27 patients who had laser treatment reported cessation of itching and pain/discomfort; and 26/27 women demonstrated visible improvement of skin color, elasticity, vascularity following 3-4 laser treatments. All examinations were performed with the operating microscope.

Conclusions

The fractional CO₂ laser beam is useful for treating vaginal atrophy and lichen sclerosis. This new technique represents a significant divergence from estrogenic-, steroid- and corticosteroid-bulwark dependence. All treatments were performed in an office setting and were associated with either no pain or, at the most, minimal and temporary discomfort. This new use of the CO₂ laser is an excellent alternative for managing these two troublesome problems, particularly in postmenopausal women.

Fractional CO₂ laser treatment: A novel approach for stress urinary incontinence management in post-menopausal women

González Isaza P¹, Ruiz Rosas AI², Vélez Rizo DL³

1: Universidad Militar de Colombia, Bogotá – Colombia. 2: Universidad Nacional de Colombia, Bogotá - Colombia.
3: Universidad de la Sabana, Bogotá - Colombia.



Abstract

Objective

To describe the results of the fractional CO₂ laser as an alternative treatment for stress urinary incontinence in post-menopausal women, and to demonstrate an improvement in quality of life after the treatment.

Materials and Methods

A prospective, single centre descriptive study was conducted on 10 post-menopausal patients with diagnosis of stress urinary incontinence. Recruited patients were evaluated with Stress Cough test and urethral Mobility Q-Tip Test, which confirmed the diagnosis. They then began a 3 session treatment protocol; 1 every 3 weeks using the SmartXide² V²LR fractional microablative CO₂ laser system for the MonaLisa Touch™ procedure in the urethrovesical junction. The Urogenital Distress Inventory UDI-6 was performed to evaluate severity and quality of life impact related to stress urinary incontinence in the patients included in the study, before and after treatment. Patients were monitored from July to December 2013.

Results

Analysis of the UDI-6 Scores before and at the end of treatment showed an improvement in the score in comparison to the baseline condition, indicating a subjective improvement in all the symptoms related to SUI included in the score.

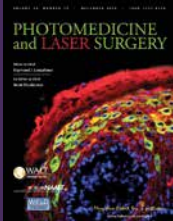
Conclusions

The MonaLisa Touch™ procedure performed with SmartXide² V²LR laser system is a complementary alternative to traditional surgical techniques, providing a safe and effective treatment for urinary incontinence in post-menopausal women.

Fractional CO₂ laser: From skin rejuvenation to vulvo-vaginal reshaping

Filippini M¹, Del Duca E², Negosanti F^{2,3}, Bonciani D⁴, Negosanti L⁵,
Sannino M², Cannarozzo G², Nisticò SP^{2,6}

1: Hospital State of Republic of San Marino - Republic of San Marino. 2: University of Rome Tor Vergata, Rome - Italy,
3: Dermatology Center, Bologna - Italy . 4: Piero Palagi University Hospital, Florence - Italy.
5: S.Orsola-Malpighi University Hospital, Bologna - Italy. 6: Magna Grecia University of Catanzaro - Italy.



Abstract

Background

The CO₂ laser has become the gold standard treatment in dermatologic surgery for the treatment of a large number of skin and mucosal lesions. The introduction of the fractional micro-ablative technology represented an integration to the ablative resurfacing technique, reducing the healing time and the side effects.

Objective

Vaginal rejuvenation performed with this technique is a minimally invasive procedure that stimulates internal tissues of the female lower genital tract to regenerate the mucosa, improving tissue trophism and restoring the correct functionality.

Methods

In our experience, 386 menopausal women affected with vulvo-vaginal atrophy (VA) were treated with three sessions of fractional micro-ablative CO₂ laser.

Results

After three treatments, patients reported a complete improvement of the symptoms (59.94% dryness, 56.26% burn, sensation, 48.75% dyspareunia, 56.37% itch, 73.15% soreness, and 48.79% vaginal introitus pain).

Conclusions

Fractional micro-ablative CO₂ laser seems to reduce symptoms related to vaginal atrophy. The beneficial effects were reported just after the first session and confirmed 12 months after the last session.

Use of a novel fractional CO₂ laser for the treatment of genitourinary syndrome of menopause: 1-year outcomes

Sokol ER¹, Karram MM²

1: Stanford University, Stanford, CA - USA. 2: The Christ Hospital, Cincinnati, OH - USA.



Abstract

Objectives

To assess safety and efficacy of a fractional CO₂ laser therapy for the treatment of genitourinary syndrome of menopause (GSM) with follow-up to 1 year posttreatment.

Methods

Women presenting with GSM and meeting inclusion criterion were enrolled. Visual Analog Scales were used to grade vaginal pain, burning, itching, dryness, dyspareunia, and dysuria. Dilators were used to rate vaginal elasticity at baseline and at each follow-up visit. Before each treatment and at follow-up, Vaginal Health Index scoring and Female Sexual Function Index questionnaires were completed. Women received three vaginal laser treatments spaced 6 weeks apart. Participant satisfaction was measured on 5-point Likert scales (1=very dissatisfied, 5=very satisfied).

Results

Of 30 women (mean age 58.6±8.8 years), three were lost to follow-up at 3 months and six at 1 year. None were discontinued or withdrew due to an adverse event. Average improvement in Visual Analog Scale scores for all symptom categories was statistically significant at 3 months and remained so through 1 year, except dysuria. Differences between data at 3 months and 1 year were not statistically significant, indicating persistence of positive outcomes. Average overall improvement in pain was 1.9 (±3.4), burning 1.9 (±3.1), itching 1.4 (±1.9), dryness 5.9 (±2.8), dyspareunia 4.9 (±3.3), and dysuria 0.9 (±3.1). Improvement in average Vaginal Health Index and Female Sexual Function Index scores was also statistically significant (P<0.0001). Of 19 women undergoing dilator examination at 1 year, 18 (94.8%) were comfortable with the same or larger dilator size. Twenty-two of 24 women (92%) were satisfied or extremely satisfied with the treatment at 1 year.

Conclusions

Based on study data up to 1 year, the fractional CO₂ laser may be an effective and safe treatment for women suffering from symptoms of GSM, although additional studies with larger populations and placebo control is needed to confirm these results.

Safety and long-term efficacy of fractional CO₂ laser treatment in women suffering from genitourinary syndrome of menopause

Behnia-Willison F^{1,2}, Sarraf S³, Miller J⁴, Mohamadi B¹, Care A S^{4,5},
Lam A⁶, Willison N², Behnia L⁷, Salvatore S⁸

1: FBW Gynaecology Plus - Australia. 2: Flinders University - Australia. 3: Virginia Women's Center - USA.

4: The University of Adelaide - Australia. 5: Robinson Research Institute - Australia.

6: Centre for Advanced Reproductive Endosurgery - Australia. 7: University of Tehran - Iran. 8: San Raffaele Hospital - Italy.



Abstract

Objective

To evaluate the safety and long-term efficacy of fractional CO₂ laser treatment in reducing the severity of symptoms of genitourinary syndrome of menopause (GSM) in menopausal women.

Study Design

102 women presenting with symptomatic GSM were treated with the fractional CO₂ laser (MonaLisa Touch, DEKA) system across a series of treatments delivered at intervals of six or more weeks. The Australian Pelvic Floor Questionnaire was used to gather data on sexual function and side-effects at three time-points across the study period (prospective panel design study). Wilcoxon signed-rank tests were used to detect statistically and clinically significant changes in sexual function and side-effects occurring from pre- to post-treatment. The primary outcome of this study was an improvement of the symptoms of GSM. The secondary outcome included bladder function and prolapse symptoms.

Results

A total of 102 women suffering from moderate to severe GSM were recruited. Eighty-four percent experienced significant improvement in their symptoms after CO₂ laser treatment. Scores on measures of sexual function, dyspareunia, and bothersomeness of sexual issues were improved from pre-treatment to long-term (12–24 month) follow-up. Furthermore, there were improvements on measures of bladder function ($P = 0.001$), prolapse ($P = 0.001$), vaginal sensation ($P = 0.001$), vaginal lubrication ($P < 0.001$) and urge incontinence ($P = 0.003$) from the pre-treatment assessment to the second assessment (i.e. after the third treatment).

Conclusions

In this study, fractional microablative CO₂ laser treatment was associated with an improvement in symptoms of GSM and sexual function.

Climacteric - Epub 2017 May 15

Fractional CO₂ laser therapy: A new challenge for vulvovaginal atrophy in postmenopausal women

Siliquini GP¹, Tuninetti V², Bounous VE², Bert F³, Biglia N²

1: Sedes Sapientiae Institute, Turin - Italy. 2: Umberto I Hospital, University of Turin, Turin - Italy. 3: University of Turin, Turin - Italy.



Abstract

Objectives

To evaluate the effects of CO₂ laser in the treatment of vulvovaginal atrophy (VVA) in postmenopausal women.

Methods

VVA was assessed in 87 postmenopausal women (mean age 58.6±6.9 years) before and after the treatment. The protocol consisted of three monthly treatments and included the treatment of vulva. Subjective measures included VAS (Visual Analog Scale) both for vaginal dryness and dyspareunia; DIVA (Day-by-day Impact of Vaginal Aging); a questionnaire on treatment satisfaction and one about the degree of pain during the procedure. Objective measures included VHI (Vaginal Health Index) and VVHI (Vulvo-Vaginal Health Index). Time points of the study were at the screening visit (T0), at baseline (T1), at week 4 (T2), at week 8 (T3), after 3 months since the last laser application (T4), after 6 months (T5), after 9 months (T6), after 12 months (T7) and after 15 months (T8).

Results

Treatment induced significant improvement in the VAS score. After treatment, VHI and VVHI indicated no VVA and this improvement was long lasting. Multivariate analysis showed that the time of follow-up was correlated with better VHI and VVHI ($p < 0.001$). DIVA improved over time ($p < 0.001$).

Conclusions

This study shows that CO₂ laser treatment induces a significant and long-lasting improvement of symptoms.

Long-term effect of thermoablative fractional CO₂ laser treatment as a novel approach to urinary incontinence management in women with genitourinary syndrome of menopause

González Isaza P¹, Jaguszewska K^{2,3}, Cardona JL⁴, Lukaszuk M³

1: San Jorge University Hospital, Pereira - Colombia. 2: Medical University of Gdansk, Gdansk - Poland. 3: Medical Centre Nowe Orłowo, Gdynia - Poland. 4: Technological University of Pereira, Pereira - Colombia.



Abstract

Introduction and Hypothesis

The aim of this study was to evaluate the long-term effect of thermoablative fractional CO₂ laser (TACO2L) as an alternative treatment for early stages of stress urinary incontinence (SUI) in postmenopausal women with genitourinary syndrome of menopause.

Methods

A total of 161 postmenopausal patients (age 53.38 ± 5.1 years, range 45-65 years) with a clinical diagnosis of mild SUI were prospectively enrolled in the study. Patients received one treatment with TACO2L every 30-45 days, each treatment comprising four sessions, followed in all patients by a yearly treatment session at 12, 24 and 36 months. SUI was evaluated using the International Continence Society 1-h pad test and the International Consultation on Incontinence Questionnaire-Urinary Incontinence Short Form (ICIQ-UI SF) before and after TACO2L treatment.

Results

TACO2L treatment was associated with a significant improvement in ICIQ-UI SF scores and 1-h pad weight test at 12 months (both $p < 0.001$), 24 months (both $p < 0.001$) and 36 months (both $p < 0.001$). Improvements were maintained for up to 36 months without the need for any further intervention. The results were confirmed by significant histological changes related to trophic restoration of the vagina, responsible for extrinsic and intrinsic mechanisms involved in urinary continence.

Conclusions

Our results suggest that TACO2L is an efficient and safe novel treatment strategy in patients with mild SUI. Further investigation to confirm the long-term results presented here is still warranted.

Laser therapy for the genitourinary syndrome of menopause. A systematic review and meta-analysis

Pitsouni E¹, Grigoriadis T¹, Falagas M^{2,3}, Salvatore S⁴, Athanasiou S¹

1: Alexandra Hospital, National and Kapodistrian University of Athens, Athens - Greece.

2: Alfa Institute of Biomedical Sciences (AIBS), Athens - Greece, Henry-Dunant Hospital Center, Athens - Greece.

3: Tufts University School of Medicine, Boston, MA - USA. 4: San Raffaele Hospital, Milan - Italy.



Abstract

This study aimed to identify and then synthesize all available data regarding the efficacy of laser therapy for postmenopausal women with genitourinary syndrome of menopause (GSM) with/without urinary incontinence (UI). PubMed, Scopus, Web of Science, Cochrane Library and ClinicalTrials.gov were searched in October 2016. The keywords were “laser genitourinary syndrome of menopause”, “laser vulvovaginal atrophy”, “laser vaginal atrophy” and “laser women incontinence”.

Quality of reporting and risk of bias of the included studies were assessed according to STROBE and MINORs checklists, respectively. Quality of the body of evidence was evaluated with the GRADE approach. Fourteen studies involving 542 participants were included in this systematic review and meta-analysis. All GSM symptoms (dryness/dyspareunia/itching/burning/dysuria/urgency/frequency) and UI decreased significantly and consistently in all available publications. The pooled mean differences for the various symptoms were: dryness -5.5 (95%CI: $-6.7, -4.4$; 7 studies; I²:0%), dyspareunia -5.6 (95%CI: $-6.8, -4.5$; 7 studies; I²:0%), itching -4 (95%CI: $-5.7, -2.2$; 6 studies; I²:79%), burning -3.9 (95%CI: $-5.9, -2.6$; 6 studies; I²:87%), dysuria -2.9 (95%CI: $-5.1, -0.7$; 4 studies; I²:90%) and UI -4.9 (95%CI: $-6.4, -3.4$; 2 studies; I²:0%). Because urgency/frequency was assessed by different methodologies the data could not be meta-analyzed. Furthermore, KHQ, UDI-6, MCS12/PCS12, FSFI, overall sexual satisfaction and measurements of the effect of laser therapy on the local pathophysiology improved significantly.

In conclusion, laser therapy for postmenopausal women with GSM appears promising. It may reduce symptom severity, improve quality of life of postmenopausal women and restore the vaginal mucosa to premenopausal status. However, the quality of the body of evidence is “low” or “very low” and, thus, evidence-based modification of current clinical practice cannot be suggested.

CO₂-laser for the genitourinary syndrome of menopause. How many laser sessions?

Athanasίου S¹, Pitsouni E¹, Falagas ME^{2,3}, Salvatore S⁴, Grigoriadis T¹

1: Alexandra Hospital, National and Kapodistrian University of Athens, Athens - Greece..

2: Alfa Institute of Biomedical Sciences (AIBS), Athens – Greece. Henry-Dunant Hospital Center, Athens - Greece.

3: Tufts University School of Medicine, Boston, MA –USA. 4: San Raffaele Hospital, Milan - Italy.



Abstract

Objectives

The aim of this prospective study was to assess the efficacy of 3, 4 or 5 CO₂-laser sessions for the management of the genitourinary syndrome of menopause (GSM).

Methods

Postmenopausal women with moderate to severe symptoms of dyspareunia, wanting to resume/retain sexual activity, were treated with 3–5 laser sessions depending on symptom severity/presence, sexual function, clinical findings and women's preference following the third laser application.

Main Outcomes

Severity of dyspareunia, dryness, sexual function, sexual satisfaction and frequency of sexual intercourse defined the primary outcomes. Vaginal Maturation Value (VMV) and Vaginal Health Index Score (VHIS) defined the secondary ones.

Results

Fifty-five women received three sessions, 53 an extra fourth and 22 an extra fifth. Following the third, fourth and fifth laser sessions, respectively: dyspareunia completely regressed in 15/55 (27%), 32/55 (58%) and 38/47 (81%) of participants; dryness completely regressed in 20/55 (36%), 36/55 (66%) and 44/51 (86%); normal sexual function resumed in 23/55 (41%), 37/54 (69%) and 41/49 (84%); VMV regained non-atrophic values in 29/55 (53%), 38/55 (69%) and 42/50 (84%); and VHIS regained non-atrophic values in 44/55 (80%), 53/55 (96%) and 55/55 (100%) of participants.

Conclusion

Results of this study indicate that CO₂-laser therapy may contribute to complete regression of dyspareunia and dryness and reestablishment of normal sexual function in postmenopausal women, in a dose-response manner. An extra fourth or fifth session may further increase the GSM symptom-free rate.

Current Opinion in Obstetrics and Gynecology - Epub 2017 Jul 29

Lasers for pelvic floor dysfunctions: Is there evidence?

Lang P, Karram M

The Christ Hospital, Cincinnati, OH - USA.



Abstract

Purpose of Review

The purpose of this review is to discuss the available energy sources used in the vaginal canal that are currently being promoted for certain pelvic floor conditions and explore the body of peer-reviewed literature supporting their use.

Recent Findings

The majority of research has focused on the use of fractional CO₂ laser treatment for genitourinary syndrome of menopause (GSM). Most of these studies are nonrandomized prospective studies, but their data consistently shows an improvement in symptoms without significant side effects.

Summary

Vaginal laser treatment for GSM is of particular interest to gynecologists as it provides patients with a history of estrogen receptor positive breast cancer, thromboembolic event, or other contraindication to hormone therapy, an effective treatment option. Currently, we are in the early stages of scientific investigation into the use of lasers in the treatment of pelvic floor dysfunction, but the emerging data is encouraging. The existing data is limited to mostly observational studies with additional quality randomized controlled trials and sham studies needed to ensure that physicians are providing the optimum evidence-based treatments to their patients. At the present time there is insufficient data to promote these therapies for stress incontinence, vaginal tightening, or other pelvic floor abnormalities.

Randomized, double-blind, placebo-controlled clinical trial for evaluating the efficacy of fractional CO₂ laser compared with topical estriol in the treatment of vaginal atrophy in postmenopausal women

Cruz VL, Steiner ML, Pompei LM, Strufaldi R,
Fonseca FLA, Santiago LHS, Wajsfeld T, Fernandes CE

ABC School of Medicine, São Bernardo do Campo, São Paulo – Brazil.



Abstract

Objective

The aim of the study was to evaluate efficacy of fractional CO₂ vaginal laser treatment (Laser, L) and compare it to local estrogen therapy (Estriol, E) and the combination of both treatments (Laser + Estriol, LE) in the treatment of vulvovaginal atrophy (VVA).

Methods

A total of 45 postmenopausal women meeting inclusion criteria were randomized in L, E, or LE groups. Assessments at baseline, 8 and 20 weeks, were conducted using Vaginal Health Index (VHI), Visual Analog Scale for VVA symptoms (dyspareunia, dryness, and burning), Female Sexual Function Index, and maturation value (MV) of Meisels.

Results

Forty-five women were included and 3 women were lost to follow-up. VHI average score was significantly higher at weeks 8 and 20 in all study arms. At week 20, the LE arm also showed incremental improvement of VHI score (P=0.01). L and LE groups showed a significant improvement of dyspareunia, burning, and dryness, and the E arm only of dryness (P<0.001). LE group presented significant improvement of total Female Sex Function Index (FSFI) score (P=0.02) and individual domains of pain, desire, and lubrication. In contrast, the L group showed significant worsening of pain domain in FSFI (P=0.04), but FSFI total scores were comparable in all treatment arms at week 20.

Conclusions

CO₂ vaginal laser alone or in combination with topical estriol is a good treatment option for VVA symptoms. Sexual-related pain with vaginal laser treatment might be of concern.

Microablative fractional CO₂ laser for the genitourinary syndrome of menopause: Power of 30 or 40 W?

Pitsouni E¹, Grigoriadis T¹, Falagas M^{2,3}, Tsvileka A¹, Salvatore S⁴, Athanasiou S¹

1: Alexandra Hospital, National and Kapodistrian University of Athens, Athens - Greece.

2: Alfa Institute of Biomedical Sciences (AIBS), Athens - Greece. Henry-Dunant Hospital Center, Athens - Greece.

3: Tufts University School of Medicine, Boston, MA -USA. 4: San Raffaele Hospital, Milan - Italy.



Abstract

This retrospective case-control study aimed to compare 30 versus 40 W power of CO₂ laser for the therapy of genitourinary syndrome of menopause (GSM). Postmenopausal women with severe intensity of dyspareunia and dryness were eligible to be included in this study. Primary outcomes were dyspareunia and dryness. Secondary outcomes were itching/burning, dysuria, frequency and urgency, Female Sexual Function Index (FSFI), vaginal maturation value (VMV), and Vaginal Health Index Score (VHIS).

One laser therapy was applied every month for 3 months. Outcomes were evaluated at baseline and 1 month following the 3rd therapy. Fifty (25 per group) women were included in this study. In the 30-W group, mean improvement of dyspareunia, dryness, itching/burning, FSFI, VMV, and VHIS was 6.1 ± 1.7 , 6.0 ± 1.9 , 5.9 ± 2.0 , 16.6 ± 6.7 , 29.9 ± 13.0 , and 11.0 ± 2.9 , respectively (within group comparisons all $p < 0.001$). In the 40-W group, mean improvement of dyspareunia, dryness, itching/burning, FSFI, VMV, and VHIS was 6.1 ± 1.7 , 6.5 ± 2.0 , 5.2 ± 2.5 , 14.8 ± 7.1 , 25.0 ± 13.4 , and 10.5 ± 4.1 , respectively (within-group comparisons, all $p \leq 0.001$).

Comparison between 30 and 40 W revealed that mean improvement or presence of all GSM symptoms and clinical signs was not statistically significant different. CO₂ laser therapy may improve GSM symptoms and clinical signs. This improvement did not seem to associate to power of 30 or 40 W.

Sexual function in women suffering from genitourinary syndrome of menopause treated with fractionated CO₂ laser

Salvatore S¹, Pitsouni E², Del Deo F¹, Parma M¹, Athanasiou S², Candiani M¹

1: San Raffaele Hospital, Milan - Italy. 2: Alexandra Hospital, National and Kapodistrian University of Athens, Athens - Greece.



Abstract

Introduction

Genitourinary syndrome of menopause (GSM) has a significant impact on the trophism of the genital and lower urinary tracts and can considerably impair sexual function. Fractional CO₂ laser has a regenerative effect on vulvovaginal tissue trophism after menopause.

Aim

To review the available literature on the effect of fractional CO₂ laser on the sexual function of postmenopausal women affected by GSM.

Methods

A database search was carried out using the terms CO₂ laser, vaginal atrophy, sexual function, dyspareunia, and genitourinary syndrome of menopause and excluding studies using other types of laser or including breast cancer survivors with vulvovaginal atrophy. For statistical analysis, the estimated overall laser effect was computed (when at least two studies were involved) and data type of generic inverse variance was computed using inverse variance as the statistical method, a random-effects model, and the difference in means as an effect measurement.

Main Outcome Measures

Different methods of evaluating sexual function were reported and studies were grouped and analyzed accordingly. Subjective assessment for dyspareunia was evaluated with a 10-point visual analog scale. Patient-reported outcome for an overall perception of sexual function was evaluated with a Likert scale. The Female Sexual Function Index was used as a condition-specific questionnaire.

Results

Six articles were considered for this review. A total of 273 women (mean age = 57.8 years) were treated with the same protocol in all studies. Compared with baseline, at the end of the treatment, dyspareunia significantly decreased in severity ($P < .001$), and the patient's perception of overall sexual function showed a statistically significant improvement ($P < .001$). At the last follow-up visit, the Female Sexual Function Index score for each single domain and overall score was significantly better than at entry ($P < .001$).


Conclusion

Fractional CO₂ laser can improve sexual function in postmenopausal women affected by GSM by restoring a better trophism in the lower genitourinary tract.

Long-term reliability of fractioned CO₂ laser as a treatment for vulvovaginal atrophy (VVA) symptoms

Pieralli A, Bianchi C, Longinotti M, Corioni S, Auzzi N,
Becorpi A, Fallani MG, Cariti G, Petraglia F

Careggi University Hospital, Florence - Italy.



Abstract

Purpose

The aim of this study was to evaluate long-term effects of the fractional CO₂ laser for the treatment of vulvovaginal atrophy (VVA) symptoms.

Methods

Women presenting with VVA symptoms and meeting inclusion criterion were enrolled to fractioned CO₂ laser therapy. Patient's satisfaction was measured on five-point Likert scale at 4 weeks and 6, 12, 18, 24 months after treatment by interview and clinical examination for vaginal livability.

Results

184 patients constituted the final study group: 128 women were spontaneous menopause and 56 were oncological menopause. 117 women were nulliparous and 36 had previous hysterectomy. 95.4% (172/184) of the patients declared that they were satisfied or very satisfied with the procedure at 4 weeks after treatment. At 6 months 92% (170/184) patients were satisfied; at 12 months 72% (118/162) were satisfied; at 18 months 63% (60/94) were satisfied; at 24 months 25% (4/16) of patients answered they were still satisfied. We observed a decline in patient's satisfaction between 18 and 24 months after laser therapy. Data showed that the time interval from onset of menopause was a statistically significant factor ($p < 0.05$) for treatment satisfaction in oncological group.

Conclusions

Long-term data showed that the improvement of vaginal health may continue up to 24 months after fractional CO₂ laser treatment although between 18 and 24 months benefits decline, and approximately 80% of women decide to start a new treatment cycle of laser applications.

Fractional CO₂ laser of the vagina for genitourinary syndrome of menopause: Is the out-of-pocket cost worth the outcome of treatment?

Lang P¹, Dell JR², Rosen L³, Weiss P⁴, Karram M¹

1: The Christ Hospital, Cincinnati, OH - USA. 2: Institute for Female Pelvic Medicine, Knoxville, TN - USA. 3: Fairfax OB-GYN Associates, Gainesville, VA - USA. 4: Roxbury Surgical Center, Beverly Hills, CA - USA.



Abstract

Objectives

The purpose of this study is to assess patient's satisfaction treatment outcomes and out-of-pocket expense for the fractional CO₂ laser (SmartXide) in the treatment of genitourinary symptoms of menopause (GSM).

Materials and Methods

A multicenter retrospective cohort study of patients who completed a course of three vaginal treatments with the SmartXide Fractional CO₂ laser. Patients contacted via telephone and asked to participate in questionnaires to evaluate for adverse outcomes since last treatment, symptom severity before and after treatment, patient satisfaction with treatment, patient satisfaction with out-of-pocket expense, and sexual function.

Results

Of the 368 patients contacted, 122 agreed to be interviewed. No patients reported seeking emergent medical treatment. Patient reported vaginal dryness significantly improved following treatment ($P < 0.05$). The frequency of intercourse increased from "once a month" to "few times a month" ($P < 0.001$). The vast majority of patients reported being satisfied with their treatment results (86%) and with the cost of treatment (78%). Satisfaction with the out-of-pocket expense did not correlate with household income ($P = 0.07$).

Conclusions

The SmartXide Fractional CO₂ laser is a safe and efficacious treatment for GSM. This treatment is associated with a high level of patient satisfaction with both treatment results and out-of-pocket expense.

Fractional microablative CO₂ laser in breast cancer survivors affected by iatrogenic vulvovaginal atrophy after failure of nonestrogenic local treatments: a retrospective study

Pagano T, De Rosa P, Vallone R, Schettini F, Arpino G, Giuliano M, Lauria R, De Santo I, Conforti A, Gallo A, Nazzaro G, De Placido S, Locci M, De Placido G

University of Naples Federico II, Naples - Italy.



Abstract

Objective

Vulvovaginal atrophy (VVA) is a condition frequently observed in menopause. Its symptoms can significantly affect the quality of life of patients. Since VVA is related to estrogen deficiency, chemotherapy and hormone therapy for breast cancer (BC) might cause VVA by inducing menopause. Given the lack of effective treatment for VVA in BC survivors, we retrospectively evaluated the efficacy and tolerability of fractional microablative CO₂ laser therapy in these patients.

Methods

We treated 82 BC survivors with three cycles of CO₂ laser after failure of topical nonestrogenic therapy. The severity of symptoms was assessed with a visual analog scale (VAS) at baseline and after completion of laser therapy. Differences in mean VAS scores of each symptom before and after treatment were assessed with multiple t tests for pairwise comparisons. Multivariate analyses were used to adjust the final mean scores for the main confounding factors.

Results

Pre versus post-treatment differences in mean VAS scores were significant for sensitivity during sexual intercourse, vaginal dryness, itching/stinging, dyspareunia and dysuria ($P < 0.001$ for all), bleeding ($P = 0.001$), probe insertion ($P = 0.001$), and movement-related pain ($P = 0.011$). Multivariate analyses confirmed that results were significant, irrespective of patients' age and type of adjuvant therapy.

Conclusions

This study shows that CO₂ laser treatment is effective and safe in BC patients with iatrogenic menopause. However, the optimal number of cycles to administer and the need for retreatment remain to be defined. Prospective trials are needed to compare CO₂ laser therapy with therapeutic alternatives.

Early regenerative modifications of human postmenopausal atrophic vaginal mucosa following fractional CO₂ laser treatment

Salvatore S¹, França K², Lotti T³, Parma M¹, Palmieri S¹, Candiani M¹, D'Este E⁴, Viglio S⁴, Icaro Cornaglia A⁴, Farina A⁴, Riva F⁴, Calligaro A⁴, Lotti J³, Wollina U⁵, Tchernev G⁶, Zerbinati N⁷

1: San Raffaele Hospital, Milan - Italy. 2: University of Miami School of Medicine, FL - USA. 3: University G. Marconi of Rome, Rome - Italy. 4: University of Pavia, Pavia - Italy. 5: Städtisches Klinikum Dresden, Dresden - Germany. 6: Medical Institute of Ministry of Interior Department of General, Vascular and Abdominal Surgery, Sofia - Bulgaria. 7: University of Insubria, Varese - Italy.



Abstract

Background

Postmenopausal women experience undesired symptoms that adversely affect their quality of life. In the recent years, a specific 12 - week fractional CO₂ laser treatment has been introduced, with highly significant relief of symptoms.

Aim

The aim of this paper is the identification of the early modifications of structural components of atrophic vaginal mucosa induced by laser irradiation, which is responsible for the restorative processes.

Materia and Methods

We investigated by microscopical, ultrastructural and biochemical methods the modifications of the structural components of postmenopausal atrophic vaginal mucosa tissues after 1 hour following a single fractional laser CO₂ application.

Results

In one hour, the mucosal epithelium thickens, with the maturation of epithelial cells and desquamation at the epithelial surface. In the connective tissue, new papillae indenting the epithelium with newly formed vessels penetrating them, new thin fibrils of collagen III are also formed in a renewed turnover of components due to the increase of metalloproteinase - 2. Specific features of fibroblasts support stimulation of their activity responsible of the renewal of the extracellular matrix, with an increase of mechanical support as connective tissue and stimulation of growth and maturation to epithelium thanks to new vessels and related factors delivered.

Conclusion

We found the activation of regenerative mechanisms expressed both in the connective tissue - with the formation of new vessels, new papillae, and new collagen - and in the epithelium with the associated thickening and desquamation of cells at the mucosal surface.

Fractional CO₂ laser for genitourinary syndrome of menopause in breast cancer survivors: clinical, immunological, and microbiological aspects

Becorpi A¹, Campisciano G², Zanotta N², Tredici Z¹, Guaschino S¹, Petraglia F¹,
Pieralli A¹, Sisti G¹, De Seta F^{2,3}, Comar M^{2,3}

1: Careggi University Hospital, Florence - Italy.

2: Institute for Maternal and Child Health "Burlo Garofolo", Trieste - Italy. 3: University of Trieste, Trieste - Italy.



Abstract

The composition of vaginal microbiome in menopause and cancer survivor women changes dramatically leading to genitourinary syndrome of menopause (GSM) in up to 7% of patients. Recent reports suggest that laser therapy may be valuable as a not hormonal therapeutic modality. The aim of the present study was to evaluate the effects of fractional CO₂ laser treatment on the vaginal secretory pathway of a large panel of immune mediators, usually implicated in tissue remodeling and inflammation, and on microbiome composition in postmenopausal breast cancer survivors. The Ion Torrent PGM platform and the Luminex Bio-Plex platform were used for microbiome and immune factor analysis. The significant reduction of clinical symptoms and the non-significant changes in vaginal microbiome support the efficacy and safety of laser treatment. Moreover, the high remodeling status in vaginal epithelium is demonstrated by the significant changes in inflammatory and modulatory cytokine patterns. Laser therapy can be used for the treatment of GSM symptoms and does not show any adverse effects. However, further studies will be needed to clarify its long-term efficacy and other effects.



Menopause -Vol.25, No.2, 2018

Response to letter to editor

Sokol ER

Stanford University, Stanford, CA - USA.

Excerpt

In Reply:

[...] Although a full discussion of the mechanism of action, safety, and efficacy of FCL for the treatment of GSM is beyond the scope of this response, the authors of this letter rightly raise some important issues surrounding this emerging therapy. I agree that FCL is being heavily marketed and patients often do not have accurate information with which to base a decision regarding proceeding with treatment. Unfortunately, FCL is not covered by insurance, so patients have to pay out of pocket. I hope this changes in the future. I agree that many physicians and health practitioners are beginning to offer this treatment, with minimal experience regarding the technical aspects of the therapy as well as a lack of understanding of mechanism of action and scientific validity of effectiveness. We are indeed in the hype cycle and quickly approaching the "peak of inflated expectation" (https://en.wikipedia.org/wiki/Hype_cycle), with numerous other energy sources now being marketed with minimal to no data. As the proverbial saying goes, the only way to go is down from here.

So what is the best way forward? We will get to that. But first, a brief response to the three reported cases highlighting possible "severe" adverse side effects to FCL in this article:

Case 1: A 53-year-old woman reported intense itching after a second FCL treatment for vaginal atrophy, but was found to have a vaginal infection, which was treated with antibiotics. She carries a diagnosis of interstitial cystitis and had undergone chemotherapy for breast cancer.

Although it is very possible that her itching is related to the FCL treatment, she has some confounding factors that may have contributed to her symptomatology including progressive atrophy, possible adverse reaction to a medication she may have been taking, and a vaginal infection. This case highlights the importance of proper patient selection for FCL therapy. In our studies, we did not see any major adverse events (including itching), but patients were carefully screened to ensure they were appropriate candidates and did not have confounding health conditions. [...]

The effects of fractional microablative CO₂ laser therapy on sexual function in postmenopausal women and women with a history of breast cancer treated with endocrine therapy

Gittens P¹, Mullen G²

1: Philadelphia Center for Sexual Medicine, Philadelphia, PA - USA.

2: Drexel University College of Medicine, Philadelphia, PA - USA.



Abstract

Purpose

To examine the outcomes of sexual function in postmenopausal women and women with a history of breast cancer treated with endocrine therapy who were experiencing the symptoms of GSM for which they were treated with fractional microablative CO₂ laser.

Methods

From July 2015 to October 2016, a retrospective chart review of women who underwent fractional microablative CO₂ laser therapy (MonaLisa Touch, DEKA) for GSM was conducted. Several validated questionnaires were used to assess changes in symptoms and sexual function including the Female Sexual Function Index (FSFI), the Wong-Baker Faces Scale (WBFS), and the Female Sexual Distress Scale-Revised (FSDSR). Comparisons of mean symptom scores were described at baseline and six weeks after each treatment.

Results

There was a statistically significant improvement in every domain of FSFI, WBFS, and FSDS-R when comparing baseline symptom scores to after treatment three symptom scores for all patients. The secondary outcome was to evaluate the differences, if any, in outcomes of sexual function between postmenopausal women and women with a history of breast cancer treated with endocrine therapy. Both groups had statistically significant improvements in many domains studied.

Conclusions

Fractional microablative CO₂ laser therapy (MonaLisa Touch, DEKA) is an effective modality in treating the symptoms of GSM in postmenopausal women and women with a history of breast cancer treated with endocrine therapy.

Gynécologie Obstétrique Fertilité & Sénologie - Epub 2018 Sep 18

CO₂ LASER for the treatment of vaginal symptoms of genitourinary syndrome of menopause

Jardin I, Canlorbe G, Mergui JL, Nikpayam M, Belghiti J, Uzan C, Azaïs H

Hôpital Universitaire Pitié-Salpêtrière-Charles-Foix, Paris - France.



Abstract

Genitourinary syndrome of menopause (GSM) brings together a collection of signs including vaginal dryness, burning sensation and itching discomfort as well as deterioration of sexual health, dysuria, urgenturia and repeated urinary infections and may be responsible for a significant impairment of quality of life in symptomatic postmenopausal women. The management of GSM therefore represents a public health issue. Systemic or local hormonal treatments are frequently offered, as well as non-hormonal treatments. The existence of contraindications to hormonal treatments and the constraints of using local treatments lead us to propose other therapeutic options. CO₂ LASER is now part of the therapeutic arsenal for the treatment of vaginal dryness in the context of GSM. There is a growing interest in this technique, especially for women who have a contraindication to hormonal therapy, as it is a globally effective, long-acting alternative with very little adverse effect. Current evidence suggests that this tool could provide a quality of life benefit to many patients with minimal side effect exposure, if used in the respect of its indications and implementation protocols. However, clinical data based on high-level therapeutic trials remain absolutely essential for this treatment to be validated and recommended by health professionals.

Menopause - Epub 2018 Sep 24

Microablative fractional CO₂ laser for the genitourinary syndrome of menopause: Up to 12-month results

Athanasίου S¹, Pitsouni E¹, Grigoriadis T¹, Zacharakis D¹, Falagas ME^{2,3,4}, Salvatore S⁵, Protopapas A¹, Loutradis D¹

1: Alexandra Hospital, National and Kapodistrian University of Athens, Athens - Greece.

2: Alfa Institute of Biomedical Sciences, Athens - Greece. 3: Henry Dunant Hospital Center, Athens - Greece.

4: Tufts University School of Medicine, Boston, MA - USA. 5: San Raffaele Hospital, Milan - Italy.



Abstract

Objectives

The aim of this study is to assess the efficacy of microablative fractional CO₂ laser therapy for genitourinary syndrome of menopause (GSM) management, when three, four, or five laser therapies were applied in a follow-up period of 12 months.

Methods

Retrospective study evaluating GSM symptoms at baseline, and 1, 3, 6, and 12 months after last laser therapy. Visual analog scale, International Consultation on Incontinence Questionnaires- Female Urinary Tract Symptoms, International Consultation on Incontinence Questionnaires-Urinary Incontinence Short Form, Urogenital Distress Inventory-6, and Female Sexual Function Index were used for assessment of GSM symptoms' intensity or bothering and parameters of sexual function.

Results

Overall, 94 women were included (35, 35, and 24 received three, four, and five therapies, respectively). All GSM symptoms improved statistically significantly. Intensity of dyspareunia and dryness decreased from 9 (5-10) (median [minimum-maximum]) and 8 (0-10) at baseline to 0 (0-6) and 0 (0-8), 1 month after last laser therapy (all $P < 0.001$), respectively. FSFI and frequency of sexual intercourse increased from 10.8 (2-26.9) and 1 (0-8) at baseline to 27.8 (15.2-35.4) and 4 (2-8) 1 month after last laser therapy (all $P < 0.001$), respectively. The positive laser effect remained unchanged throughout the 12 months of follow-up. The same pattern was followed for symptom-free rates. Four or five laser therapies may be superior in lowering the intensity of GSM symptoms in comparison to three laser therapies, in short and long-term follow-up. Differences between four and five laser therapies were not found.

Conclusions

Laser therapy may provide significant improvement and/or absence of GSM symptoms up to 12 months follow-up, irrespectively to the number of laser therapies applied. Symptoms intensity 1 month after last laser therapy may be indicative of GSM symptoms intensity at 12 months. One month after third laser therapy is the critical time to decide whether treatment extension should be offered.

How I do? A treatment with fractional CO₂ LASER for vulvovaginal atrophy symptoms in menopausal women

Jardin I¹, Louis-Vahdat C², Canlorbe G¹, Mergui JL¹, Uzan C¹, Azaïs H¹

1: Hôpital Universitaire Pitié-Salpêtrière-Charles-Foix, Paris - France. 2: Paris - France.



Abstract

Objectives

The objective of this article is to describe the physical principles and technical methods of using a CO₂ fractional LASER. The parameters discussed are those available on the DEKA Mona Lisa Touch device of which we have experience.

Methods

Materials used are : protective eyewear ; LASER source ; probes: different probes are available depending on the area to be treated, the extent of vaginal atrophy, the caliber of the probe and the type of treatment. the area to be treated, the extent of vaginal atrophy, the calibre of the vagina. of the vagina. The practitioner, his assistants and the patient must systematically wear the protective goggles before turning on the device. The LASER device is locked annually with a security key. The vaginal probe or handpiece is then connected to the LASER source and to a ventilation system. The different operating parameters of the vaginal LASER are selected manually on the device.

Conclusions

Provided that it is used under rigorous conditions and in accordance with its indications, fractional vaginal LASER with CO₂ seems to constitute an effective treatment modality, well tolerated, and without major complications. This strategy has been developed over the last few months and seems to bring an improvement in symptoms, in particular for women with a contraindication to hormonal treatments.

Fractional CO₂ laser for treatment of stress urinary incontinence

Behnia-Willison F^{1,2,3}, Nguyen TTT^{2,3}, Mohamadi B³, Vancaillie TG⁴,

Lam A⁵, Willison NN¹, Zivkovic J¹, Woodman RJ¹, Skubisz MM⁶

1: Flinders University, Adelaide - Australia. 2: Flinders Medical Center, Adelaide - Australia.

3: FBW Gynaecology Plus, - Australia. 4: University of New South Wales, Sydney - Australia.

5: University of Sydney, Sydney - Australia. 6: Women's and Children's Hospital, Adelaide - Australia.



Abstract

Objectives

To evaluate the impact of trans-vaginal fractional CO₂ laser treatment on symptoms of stress urinary incontinence (SUI) in women.

Study Design

Women clinically diagnosed with SUI preferring non-surgical treatment were recruited to the study. Fractional CO₂ laser system (MonaLisa T, DEKA) treatments were administered trans-vaginally every 4-6 weeks for a total of three treatments. Response to treatment was assessed at baseline (T1), at 3 months after treatment completion (T2) and at 12-24-month follow-up (T3) using the Australian Pelvic Floor Questionnaire (APFQ). The primary outcome was changes in reported symptoms of SUI. Secondary outcomes assessed included bladder function, urgency, urge urinary incontinence (UUI), pad usage, impact of urinary incontinence on quality of life (QOL) and degree of bothersome bladder.

Results

Fifty-eight women were recruited and received the study treatment protocol. Eighty-two percent of participants reported an improvement in symptoms of SUI at completion of treatment (mild to no SUI) ($p = <0.01$). Treatment effect waned slightly when assessed at follow-up. Nevertheless, 71% of participants reported ongoing improvement in SUI symptoms at 12-24 months ($p < 0.01$). All secondary outcome measures were improved after treatment compared to baseline.

Conclusions

This study suggests that fractional CO₂ laser is a safe, feasible, and beneficial treatment for SUI and may have a role as a minimally-invasive alternative to surgical management.

Efficacy of fractional CO₂ laser in the treatment of genitourinary syndrome of menopause in Latin-American population: First Peruvian experience

Tovar-Huamani J¹, Mercado-Olivares F², Grandez-Urbina JA^{3,4},
Pichardo-Rodriguez R^{4,5}, Tovar-Huamani M¹, García-Perdomo H⁶

1: Clinica CIRUFEME, Lima - Perú. 2: Universidad San Martín de Porres, Lima - Perú. 3: Universidad Continental, Lima - Perú.
4: Clínica UROZEN, Lima - Perú. 5: Universidad Ricardo Palma, Lima - Perú. 6: Universidad Del Valle, Cali - Colombia.



Abstract

Objectives

This PUBA study aimed to assess the efficacy of fractional CO₂ laser in the treatment of genitourinary syndrome of menopause (GSM).

Methods

GSM symptoms were assessed before, 1 month after the first session and 1 month after the third session of laser (3 sessions with a 30 days interval between them) in 60 women (median, interquartile range: 55, 49-69). Subjective (visual analog scale) and objective (Vaginal Health Index, VHIS; Vaginal Maturity Index/ Frost Index; Spanish Overactive Bladder Questionnaire-Short Form, USMEX Spanish OAB-qSF and Female Sexual Function Index, FSFI) measures were used during the study period to assess CO₂ fractionated laser treatment outcomes compared to baseline.

Results

Fractional CO₂ laser treatment was effective to improve GSM symptoms (vaginal dryness, vaginal itching, vaginal burning, dyspareunia, dysuria, urinary urgency; $P < 0.001$) after three sessions, as well as VHIS (median, interquartile range: 13, 10-15 at baseline vs. 21, 20-23 at the fourth month follow up; $P < 0.001$), Frost Index (median, interquartile range: 28, 24-31 at baseline vs. 8, 6-10 at the fourth month follow up; $P < 0.001$), USMEX (median, interquartile range: 56, 46-68 at baseline vs 14, 13-16 at the fourth month follow up; $P < 0,001$) and FSFI (median, interquartile range: 5, 2-14 at baseline vs 30, 28-32).

Conclusions

In this sample, the data suggests that fractionated CO₂ laser is an effective alternative for GSM treatment with positive outcomes that persists over time.

Lasers in Medical Science – Epub 2019 Mar 4

In response to the FDA warning about the use of photomedicine in gynecology

Escribano JJ¹, González-Isaza P², Tserotas K³, Athanasiou S⁴,
Zerbinati N⁵, Leibaschoff G⁶, Salvatore S⁷, Sánchez-Borrego R⁸


1: Instituto Médico Laser, Madrid - Spain. 2: San Jorge University Hospital, Pereira - Colombia.

3: Complejo Hospitalario Metropolitano Caja Seguro Social, Panamá, Panamá.

4: Alexandra Hospital, National and Kapodistrian University of Athens, Athens - Greece. 5: University of Insubria, Varese - Italy.

6: General Secretary of the World Society of Cosmetic Gynecology, Dallas, TX - USA. 7: San Raffaele Hospital, Milan - Italy.

8: Diatros Medical Centre, Barcelona - Spain.



Abstract

To alert patients and health care providers about the use of energy-based devices to perform a vaginal "rejuvenation," cosmetic vaginal procedures, or nonsurgical vaginal procedures to treat symptoms related to menopause, urinary incontinence, or sexual function, the US Food and Drug Administration (FDA) has issued a warning about the effectiveness and safety of such devices. We agree with the FDA that certain devices (laser, radiofrequency, etc.) have been marketed inappropriately for uses that are outside of their cleared or approved intended uses. We want to position ourselves in the strict training of professionals so that the indications and techniques are used in the best possible way, knowing that, similar to any medical or surgical technique, the side effects can appear in the short and long term, and should be recognized and remedied.



Menopause – Epub 2019 Apr 15 Letter to the editor

Karram M, Stachowicz A
The Christ Hospital, Cincinnati, OH - USA.

Excerpt

To the editor:

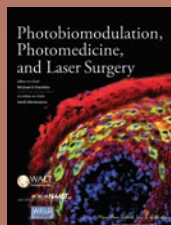We read with interest the article, “Rethinking the techno vagina: a case series of patient complications following vaginal laser treatment for atrophy,” by Gordon et al, published in Volume 26, Number 4 of Menopause. We agree that laser treatment for genitourinary syndrome of menopause (GSM) is a relatively new use of this technology and should be scrutinized in regards to potential efficacy and complications and that more long-term data on this technology would be welcome. We have, however, concerns regarding how the authors define a complication. The cases described patients who presented with symptoms of GSM, had a series of laser treatments, and then continued to experience the same or perceived worsening of the same symptoms. To brand these outcomes as complications of the laser treatments is arguably an incorrect usage of the term, complication. As GSM is a clinical diagnosis where treatments have patient-derived outcomes, a lack of objective data exists to support their assumption that persistent symptoms were a direct result of the laser. We do not consider persistent urinary incontinence a complication of midurethral sling, rather it is a potential outcome. Likewise, persistent dyspareunia after vaginal laser treatment should be classified as the latter and the patients who experience persistent symptoms are either nonresponders or were not appropriate candidates to begin with. The authors had no information regarding pretreatment examinations or how the laser treatments were delivered. Since 2014, our center has utilized a fractional CO₂ laser (SmartXide Touch; DEKA, Florence, Italy) on hundreds of patients with GSM, and has published results on treatment of approximately 200 patients on research protocols. Our experience indicates that in appropriately selected patients the treatment is very safe and produces subjective success rates in the 85% range, defining success as the patient stating she was happy with the outcome and felt the out-of-pocket costs were worth the results she achieved. Furthermore, persistence of positive outcomes at 1 year has been reported. To date, there are 37 peer-reviewed publications noting favorable outcomes with minimal adverse events. [...]

Case report: Treatment for rectovaginal fistula in Crohn's disease using fractionate CO₂ vaginal laser with anti-TNF therapy

Drumond DG¹, Chebli JMF¹, Speck NMG², Chebli LA¹, Pannain GD¹, Esperança SD¹, Condé CMS³

1: Universidade Federal de Juiz de Fora, Juiz de Fora - Brazil.

2: Federal University of São Paulo, Sao Paulo - Brazil. 3 : Ultrimagem, Juiz de Fora - Brazil.



Abstract

Background

Rectovaginal fistulas (RVFs) are defined as any connection between the anorectum and the vagina. They can have several causes, being Crohn's disease, the second leading cause of RVFs, responsible for ~10% of the RVFs. Despite the advances in surgical and clinical treatment, there is no consensus regarding the best line of treatment.

Objective

To report another therapeutic option, we describe the case of a patient with Crohn's disease and RVF refractory to anti-tumor necrosis factor (TNF) therapy, submitted to intravaginal CO₂ fractional laser treatment.

Materials and Methods

Three laser sessions with monthly interval and analysis by clinical examination, sexual evaluation questionnaire, and magnetic resonance of the pelvis were performed.

Results

We obtained an important improvement of the symptoms and of the dimension of the fistulous path.

Conclusions

We believe this method to be a complementary, promising, and safe therapeutic alternative for the management of vaginal fistula. Future studies using this therapeutic strategy are needed to confirm the efficacy of this method in this clinical setting.



The Journal of Maternal-Fetal & Neonatal Medicine – Epub 2019 Jun 17

Postpartum perineal pain: May the vaginal treatment with CO₂ laser play a key-role in this challenging issue?

Filippini M¹, Farinelli M¹, Lopez S^{2,3}, Ettore C⁴, Gulino FA⁴, Capriglione S¹

1: Hospital State of Republic of San Marino, San Marino - Republic of San Marino.

2: Yale University School of Medicine, New Haven, CT - USA. 3: Magna Graecia University, Catanzaro - Italy.

4: ARNAS Garibaldi-Nesima, Catania - Italy.

Abstract

Purpose

Pregnancy and childbirth, despite being physiological events, represent a very delicate period in a woman's life, because they expose to important vulvo-perineal traumas. The pelvic pain that follows each delivery, whether spontaneous or surgical (caesarean section), does not end in the first days after birth but, depending on the studies, becomes persistent in a very variable percentage of cases. Therefore, in the present pilot study, we aimed, for the first time in literature, to assess the efficacy of CO₂ laser in women affected by perineal postpartum symptoms.

Materials and Methods

Between February 2013 and June 2018, all women with late postpartum pelvic pain referred to the Department of Obstetrics and Gynecology of San Marino Hospital, were recruited and treated using the CO₂ laser for three applications every 4-6 weeks.

Results

Between February 2013 and June 2018, according to the inclusion and exclusion criteria, 32 women with late postpartum pelvic pain were recruited in our protocol study. Mean age of patients was 34.1 years. At latest follow-up, our data demonstrated an improvement in symptoms (dyspareunia, pain at introitus, vaginal dryness, itching and vaginal burning) with a mean reduction of this symptom of 70% from baseline.

Conclusions

This study has shown the effectiveness of CO₂ laser treatment in postpartum perineal pain. Nevertheless, our results should be considered promising but preliminary. In fact, they need to be tested in larger cohort of patients to confirm its application in clinical practice and to evaluate the long-term duration of this treatment.

Lasers in Surgery and Medicine - Epub 2019 Jun 25

The effect of fractional CO₂ laser treatment on the symptoms of pelvic floor dysfunctions: Pelvic Floor Distress Inventory-20 Questionnaire

Sipos AG¹, Kozma B¹, Poka R¹, Larson K², Takacs P²

1: University of Debrecen Faculty of Medicine, Debrecen - Hungary.
2: Eastern Virginia Medical School, Norfolk, VA -USA.



Abstract

Background and Objectives

To assess the improvement on pelvic floor distress (PFD)-related urogenital symptoms using validated questionnaires after intravaginal CO₂ laser treatment.

Study Design/Materials and Methods

Forty postmenopausal women with genitourinary symptoms of menopause (GSM) were enrolled into this prospective cohort study and underwent vaginal laser treatment using Monalisa Touch® fractional CO₂ laser system. Patients received three vaginal laser treatments with 360° probe 4 weeks apart. A three-component Pelvic Floor Distress Inventory (PFDI-20) validated questionnaire was filled out by each patient before each session and 4 weeks after the final treatment. Wilcoxon rank sum test was used to compare the before and after treatment scores.

Results

Pelvic Organ Prolapse Distress Inventory (POPDI-6) scores were not significantly different after the first treatment compared with baseline (mean ± standard deviation [SD], 21 ± 18 vs. 17 ± 15, P=0.44). However, each subsequent treatment resulted in further, statistically significant improvement in symptom scores (14 ± 15, P=0.03 and 13 ± 13, P=0.01, after the second and third treatments, respectively). Similarly, Urinary Distress Inventory (UDI-6) scores were not significantly different after the first laser treatment (mean ± SD, 36 ± 25 vs. 29 ± 23, P=0.36). After the second and third treatments there were significant improvement in the standardized scores (24 ± 20, P=0.03 and 22 ± 21, P=0.01). Colorectal-Anal Distress Inventory (CRADI-8) scores did not change significantly after three laser treatments.

Conclusions

Three sessions of microablative fractional CO₂ vaginal laser treatment significantly improves patient reported urinary and pelvic organ prolapse symptoms.

Menopause – Vol.26, No.8, 2019

Fractional CO₂ laser versus promestriene and lubricant in genitourinary syndrome of menopause: a randomized clinical trial

Politano CA, Costa-Paiva L, Aguiar LB, Machado HC, Baccaro LF

State University of Campinas-UNICAMP Campinas, São Paulo - Brazil.



Abstract

Objectives

The aim of this study was to compare the effects of fractional CO₂ laser therapy, promestriene, and vaginal lubricants on genitourinary syndrome treatment and sexual function in postmenopausal women.

Methods

We performed a randomized clinical trial including 72 postmenopausal women over the age of 50 years. The women were randomized into three intervention groups to receive one of the following treatments: three sessions of intravaginal fractional CO₂ laser therapy; 10mg of intravaginal promestriene cream 3 times a week; and vaginal lubricant application alone. Vaginal maturation, Vaginal Health Index (VHI) score, and Female Sexual Function Index (FSFI) were evaluated at baseline and after 14 weeks of therapy.

Results

We observed an improvement in the vaginal elasticity, volume, moisture, and pH in the CO₂ laser and promestriene groups. The VHI score at 14 weeks was higher in the CO₂ laser group (mean score 18.68) than in the promestriene (15.11) and lubricant (10.44) groups ($P < 0.001$). Regarding vaginal maturation, basal cells were reduced and superficial cells were increased after treatment. This improvement was more significant in the CO₂ laser group ($P < 0.001$). The FSFI score only showed improvement in the desire and lubrication domains in the CO₂ laser group. There were no differences in total FSFI score among the three treatment groups. There were no adverse effects associated with any of the treatments.

Conclusions


The use of fractional CO₂ laser therapy to treat genitourinary syndrome resulted in better short-term effects than those of promestriene or lubricant with respect to improving the vaginal health in postmenopausal women.

Breast Cancer Res Treat - Epub 2019 Aug 3

Vaginal CO₂ laser for the treatment of vulvovaginal atrophy in women with breast cancer: LAVA pilot study

Pearson A^{1,2}, Booker A³, Tio M^{4,5}, Marx G^{2,3}

1: Royal North Shore Hospital, St Leonards, NSW - Australia. 2: University of Sydney, Sydney, NSW - Australia. 3: Sydney Adventist Hospital, Wahroonga, NSW - Australia. 4: Melanoma Institute Australia, North Sydney, NSW - Australia.



Abstract

Purpose

Vulvovaginal atrophy (VVA) is a commonly reported issue among breast cancer patients, and its aetiology is multifactorial. Treatment is difficult in these women, particularly because the use of oestrogens has traditionally been discouraged. Vaginal laser treatment has been reported to improve symptoms. We aimed to assess the impact on symptoms and sexual function of vaginal laser in women with early breast cancer (EBC).

Methods

We performed a single-arm investigator initiated pilot study of female EBC patients with symptomatic VVA. A total of 3 vaginal laser treatments were administered 4 weeks apart. Questionnaires were completed at baseline, 4, 8 and 12 weeks. Our primary endpoint was symptomatic improvement of VVA at 12 weeks on 10 cm visual analogue scales. Our secondary endpoints were improvement in sexual function using the Female Sexual Function Index (FSFI) and patient-reported improvements in symptoms, sexual function and quality of life. Statistical analysis was performed with a Wilcoxon Signed Rank test.

Results

26 patients were enrolled between February 2016 and August 2017. All patients were post-menopausal, 25 of whom had received anti-oestrogen therapy for their breast cancer. Questionnaire compliance was high (98%) and all patients received the three pre-planned treatments. There was significant improvement in each of the VVA symptoms: dryness ($p < 0.001$), itch ($p < 0.001$), burning ($p = 0.003$), dysuria ($p < 0.001$) and dyspareunia ($p < 0.001$). Patients also reported improvement in sexual function on the FSFI ($p \leq 0.001$).

Conclusions

Patients receiving vaginal laser had improvement in VVA symptoms and sexual function. Further randomised sham-controlled trials are needed to further assess this treatment.

Intravaginal energy-based devices and sexual health of female cancer survivors: a systematic review and meta-analysis

Athanasiou S¹, Pitsouni E¹, Douskos A¹, Salvatore S², Loutradis D¹, Grigoriadis T¹

1: National and Kapodistrian University of Athens, Athens - Greece. 2: San Raffaele Hospital, Milan - Italy.



Abstract

A systematic review and meta-analysis was undertaken to assess the efficacy and safety of intravaginal energy-based therapies (laser and radiofrequency) on sexual health of cancer survivors (CS) (breast cancer (BCS) and/or gynecological cancer (GCS)). PubMed, Scopus, Web of Science, and Cochrane Library were searched until 21/02/2019. Quality of reporting, methodology, and body of evidence were assessed using STROBE, MINORS, and GRADE. Primary outcomes were dyspareunia, dryness, and sexual health (FSFI, FSDS-R). Secondary outcomes were burning, itching, dysuria, incontinence, Vaginal Health Index Score (VHIS), microbiome-cytokine evaluation, and adverse events. Main analyses, subgroup analyses, and sensitivity analyses were performed. Eight observational studies (n=274) were eligible for inclusion. None of the studies evaluated radiofrequency. BCS and BCS-GCS were included in 87% and 13% of studies, respectively. All primary outcomes improved significantly with the exception of FSDS-R (dyspareuniaudies (n=233), standardized mean difference (StdMD) (-1.17), 95%CI [-1.59, -0.75]; p<0.001; I2=55%), vaginal dryness (4 studies (n=183), StdMD (-1.98), 95%CI [-3.31, -0.65]; p=0.003; I2=91%), FSFI (2 studies, n=28, MD (12.79), 95%CI [7.69, 17.89]; p<0.001; I2=0%). Itching, dysuria, and VHIS increased significantly, while burning was not improved. Serious adverse events were not observed by any of the studies. Intravaginal laser therapies appear to have a positive effect on dyspareunia, vaginal dryness, and FSFI of CS. However, the quality of evidence is "very low," with no data on intravaginal radiofrequency therapy. Further research with high-quality RCTs and long-term follow-up is needed to evaluate the value of energy-based devices as a therapeutic option for CS with sexual problems.

Neurourology and Urodynamics - Epub 2019 Aug 20

LASER users' expert opinion in response to "The clinical role of LASER for vulvar and vaginal treatments in gynecology and female urology: an ICS/ISSVD best practice consensus document"

Salvatore S¹, Athanasios S², Yuen HTH², Karram M³

1: San Raffaele Hospital, Milan – Italy. 2: National and Kapodistrian University of Athens, Athens – Greece.
3: The Christ Hospital, Cincinnati, OH - USA.



Excerpt

Letter to the editor:

We read with interest “The clinical role of LASER for vulvar and vaginal treatments in gynecology and female urology: An ICS/ISSVD best practice consensus document” by Preti et al.¹ While we welcome efforts to improve research quality in any field of our discipline, we were disappointed by the methodological confusion and incorrect statements presented. It is inappropriate to incorporate different clinical and cosmetic indications treated with LASER technology in a consensus document. The data is not presented in as an impartial fashion as one would expect for a consensus document representing two prestigious societies. Examples of inappropriate and inaccurate statements regarding LASER therapy for women with Genitourinary Syndrome of Menopause (GSM) are listed as follows:

1. It is unacceptable to include GSM and “vaginal rejuvenation” in the same category, as GSM is a true disease state, while “vaginal rejuvenation” is a poorly defined term that implies an aesthetic or cosmetic treatment. [...]

A randomized clinical trial comparing vaginal laser therapy to vaginal estrogen therapy in women with genitourinary syndrome of menopause: the VeLVET Trial

Paraiso MFR¹, Ferrando CA¹, Sokol ER², Rardin CR³, Matthews CA⁴, Karram MM⁵, Iglesia CB⁶

1: The Women's Health Institute, Cleveland, OH – USA. 2: Stanford University School of Medicine, Palo Alto, CA - USA.

3: Women and Infants Hospital, Brown University Medical Center, Providence, RI - USA.

4: Wake Forest Baptist Health, Winston Salem, NC – USA. 5: The Christ Hospital, Cincinnati, OH - USA.

6: MedStar Washington Hospital Center/Georgetown University School of Medicine, Washington, DC - USA.



Abstract

Objective

The aim of the study was to compare 6-month efficacy and safety for treatment of vaginal dryness/genitourinary syndrome of menopause in women undergoing fractionated CO₂ vaginal laser therapy to women using estrogen vaginal cream.

Methods

This multicenter, randomized trial compared fractionated CO₂ laser to estrogen cream at 6 institutions. We included menopausal women with significant vaginal atrophy symptoms and we excluded women with prolapse below stage 2, recent pelvic surgery, prior mesh surgery, active genital infection, history of estrogen sensitive malignancy, and other autoimmune conditions. The primary outcome was the visual analog scale vaginal dryness score. Secondary outcomes included evaluation of vaginal atrophy, quality of life symptoms, assessment of sexual function, and urinary symptoms. Adverse events (AEs) and patient global impression of improvement (PG-I) and satisfaction were also assessed.

Results

Sixty-nine women were enrolled in this trial before enrollment was closed due to the Federal Drug Administration requiring the sponsor to obtain and maintain an Investigational Device Exemption. Of the 69 participants enrolled, 62 completed the 6-month protocol; 30 women were randomized to the laser and 32 to estrogen cream from June 2016 to September 2017. Demographics did not differ between groups except the laser group was less parous (0 [range 0-4] vs 2 [0-6], $P = 0.04$). On patient global impression, 85.8% of laser participants rated their improvement as "better or much better" and 78.5% reported being either "satisfied or very satisfied" compared to 70% and 73.3% in the estrogen group; this was not statistically different between groups. On linear regression, mean difference in female sexual function index scores was no longer statistically significant; and, vaginal maturation index scores remained higher in the estrogen group (adj P value 0.02); although, baseline and 6-month follow-up vaginal maturation index data were only available for 34 participants (16 laser, 18 estrogen).

Conclusions

At 6 months, fractionated CO₂ vaginal laser and vaginal estrogen treatment resulted in similar improvement in genitourinary syndrome of menopause symptoms as well as urinary and sexual function. Overall, 70% to 80% of participants were satisfied or very satisfied with either treatment and there were no serious adverse events.

Short-term efficacy of vaginal CO₂ laser therapy as a treatment modality for genitourinary syndrome of menopause

Kozma B¹, Póka R¹, Sipos A¹, Ács N², Takács P³

1: Debreceni Egyetem, Debrecen - Hungary. 2: Semmelweis Egyetem, Budapest - Hungary. 3: Eastern Virginia Medical School, Norfolk, VA - USA.



Abstract

Introduction

Genitourinary syndrome of menopause (GSM) affects up to 40-57% of postmenopausal women. Intravaginal microablative fractional CO₂ laser is a new proposal for the management of GSM, although the evidence of safety and efficacy of the procedure appears to be insufficient. Aim: The aim of the study was to assess the efficacy of fractional CO₂ laser for the treatment of GSM at the Department of Obstetrics and Gynecology of the University of Debrecen.

Method

Postmenopausal women with symptoms of GSM underwent three sessions of microablative fractional rejuvenation CO₂ laser therapy at 4-6 weeks intervals. Vaginal health index (VHI) scores were completed before each treatment and at 6 weeks follow-up as an objective measurement and visual analog scale was used to assess subjective complaints. Statistical analysis included Student's paired two-sampling t-test for the measure of statistical significance using the standard cutoff for significance $p < 0.05$.

Results

51 women participated (mean age 57.0 ± 9.9 y). Average VHI score was 14.0 ± 4.9 before treatment, 15.0 ± 4.7 after the first session, 18.2 ± 4.6 after the second treatment and 19.5 ± 4.9 at follow-up. The improvement of VHI score was statistically significant between all sessions. Average VAS score was 15.6 ± 14.1 before treatment, 9.0 ± 10.8 after the first session, 5.9 ± 9.2 after the second treatment and 3.4 ± 7.5 at follow-up. The improvement of VAS score was statistically also significant between all sessions.

Conclusions


Our study suggests that the fractional CO₂ laser is an effective and safe treatment of symptoms associated with GSM.

Gynecological Endocrinology - Epub 2019 Oct 22

Ospemifene plus fractional CO₂ laser: A powerful strategy to treat postmenopausal vulvar pain

Murina F, Felice R, Di Francesco S, Nelvastellio L, Cetin I

V. Buzzi Hospital, University of Milan, Milan - Italy.



Abstract

Objective

This study is a single-center, retrospective analysis of postmenopausal women presenting with dyspareunia and vulvar pain, aiming to evaluate relative effectiveness of vestibular CO₂ laser therapy as a treatment. Three monthly sessions of laser were performed to each patient and thereafter a three-months follow-up was established. A total number of 72 patients undergoing vestibular laser treatment were recruited from patient files in the period between 2016 and 2018. Among these, 39 women also received a concomitant treatment with ospemifene (60 mg/day) during the study period. There was a statistically significant reduction of all the symptoms in both groups up to the three month follow-up. Regarding dryness and dyspareunia, the relief tent to be more prominent in the ospemifene+laser group at all follow-ups and remained statistically significant at three-month follow-up. Specifically, vestibular dryness was significantly lower in the ospemifene+laser group compared with the laser treatment group (-87% vs -34%, respectively), and the vestibular health score started declining faster in the ospemifene+laser group. Although, additional research is needed to understand the mechanism of action, our data shows that a combination regimen of laser and ospemifene may improve clinical effectiveness for long-term treatment of symptoms associated with the under-recognized genitourinary syndrome of menopause.

European Journal of Obstetrics & Gynecology
and Reproductive Biology - Epub 2019 Oct 22

Promising impact of platelet rich plasma and carbon dioxide laser for stress urinary incontinence

Behnia-Willison F^{1,2,3}, Nguyen TTT^{1,2,3}, Norbury AJ²,
Mohamadi B³, Salvatore S⁴, Lam A⁵

1: Flinders Medical Centre, Adelaide - Australia. 2: Flinders University, Adelaide - Australia.
3: FBW Gynaecology Plus, Adelaide - Australia. 4: IRCCS San Raffaele University, Milan - Italy.
5: Centre for Advanced Reproductive Endosurgery, Sydney - Australia.



Abstract

Objectives

To evaluate the safety, feasibility and efficacy of trans-vaginal fractional micro-ablative CO₂ laser therapy in combination with platelet rich plasma (PRP) for the treatment of stress urinary incontinence (SUI) in women.

Study Design

Participants with SUI underwent three sessions of transvaginal CO₂ laser and PRP treatment, administered at 4-6-week intervals. Outcomes were assessed using the bladder function section of the Australian Pelvic Floor Questionnaire (APFQ). The primary outcome was changes in the participants' symptoms of SUI. Secondary outcomes were related to general bladder function. Outcome differences from baseline (T1) to 3 months (T2) and 12 months (T3) were analysed using Wilcoxon signed-rank tests. Subjective verbal scales were used to assess the degree of pain associated with PRP injections and laser treatment.

Results

Sixty-two women with SUI were enrolled into this study. There were 66% (41/62) of participants who reported improved SUI symptoms from T1 to T2 ($p < 0.001$) and at T3, 62% (23/37) of patients reported improved SUI symptoms ($p < 0.001$). From T1 to T2, all bladder function variables were improved significantly ($p < 0.002$). At T3, significant improvements ($p < 0.03$) were maintained for all bladder function variables, except pad usage ($p = 0.073$).

Conclusions

Combining transvaginal fractional CO₂ laser with PRP might be a beneficial treatment for SUI. It may have the potential to be a minimally-invasive and low-risk alternative to surgery, with reduced recovery time.

Efficacy of fractional CO₂ laser treatment in postmenopausal women with genitourinary syndrome: A multicenter study



Filippini M¹, Luvero D², Salvatore S³, Pieralli A⁴,
Montera R², Plotti F², Candiani M³, Angioli R²

1: Hospital State of Republic of San Marino, San Marino - Republic of San Marino.
2: Campus Bio-Medico University, Rome - Italy. 3: IRCCS San Raffaele Hospital, Milan - Italy.
4: Careggi University Hospital, Florence - Italy.

Abstract

Objective

Genitourinary syndrome of menopause (GSM), especially vulvovaginal atrophy (VVA), is one of the most common conditions among women in either natural (4%-47%) or medically induced (23.4%-61.5%) menopause. The aims of this study are to assess the efficacy and effectiveness of CO₂ laser in postmenopausal women with clinical signs and symptoms of GSM, in particular VVA, and to evaluate both possible early and late side effects related to this kind of treatment.

Method

This retrospective, multicenter study was conducted after collecting data from a pre-existing database. We performed three to four CO₂ laser treatments on all the women enrolled in this protocol. We used a fractional CO₂ laser system (SmartXide2 V2LR, Deka m.e.l.a., Florence, Italy) with a VulvoVaginal Laser Reshaping (V2LR) scanning system and appropriate handpieces for the vaginal area. All women before and after the treatment were assessed. The pre- and post-treatment averages of the symptoms, the standard deviation, and the P values were calculated.

Results

Six hundred forty-five women who met the inclusion criteria were considered. In all the parameters examined (dyspareunia, vaginal orifice pain, dryness/atrophy, itching, burning, pH) statistically significant data were found between the pretreatment and the post-treatment (dryness: before=8.30, after=2.97 [P<0.0001], dyspareunia: before=8.70, after=3.51 [P<0.0001]; burning: before=6.12, after=1.78 [P<0.0001]; vaginal orifice pain: before=8.07, after=2.94 [P<0.0001]; itching: before=6.09, after=1.32 [P<0.0001]).

Conclusions

Our results show the effectiveness and a good degree of tolerance of treatment with the CO₂ laser system in postmenopausal women with GSM.

Fractional CO₂ laser therapy for genitourinary syndrome of menopause for breast cancer survivors

Quick AM¹, Zvinovski F¹, Hudson C¹, Hundley A¹, Evans C¹, Suresh A¹, Stephens JA², Arthur E¹, Ramaswamy B¹, Reinbolt RE¹, Noonan AM¹, VanDeusen JB¹, Wesolowski R¹, Stover DG¹, Williams NO¹, Sardesai SD¹, Smith KL³, Faubion SS⁴, Loprinzi CL⁴, Lustberg MB¹

1: The Ohio State University Medical Center, Columbus, OH - USA. 2: The Ohio State University Center for Biostatistics, Columbus, OH - USA. 3: Johns Hopkins Sidney Kimmel Comprehensive Cancer Center, Baltimore, MD - USA. 5: Mayo Clinic, Rochester, MN - USA.



Abstract

Purpose

Fractional CO₂ laser therapy is an emerging treatment for genitourinary syndrome of menopause (GSM). The objective of this study was to determine the feasibility and preliminary efficacy of fractional CO₂ laser therapy in breast cancer survivors.

Method

This was a single arm feasibility study of breast cancer survivors with dyspareunia and/or vaginal dryness. Participants received three treatments of fractional CO₂ laser therapy at 30-day intervals and returned for a 1-month follow-up. Feasibility was defined as treatment completion without serious adverse events (SAE) in 80% of patients. We collected data on the Vaginal Assessment Scale (VAS), the Female Sexual Function Index (FSFI), the Urinary Distress Index (UDI), and SAE.

Results

A total of 64 patients participated in the study. The majority of women had Estrogen receptor/Progesterone receptor (ER/PR) positive/Her2neu negative (n=37; 63%), stage I (n=32, 54%) or II (n=19, 32%) breast cancer. Most were receiving endocrine therapy (n=54, 92%), most commonly aromatase inhibitors (AI; n=40, 68%). Fifty-nine (88.1%) of those enrolled completed all treatments according to protocol with no reported SAE. No patient withdrew due to SAE. The scores of the VAS (mean Δ -0.99; 95% CI [-1.19, -0.79], p<0.001), FSFI (mean Δ 9.67; 95% CI [7.27, 12.1], p<0.001), and UDI (mean Δ -8.85; 95% CI [-12.75, -4.75], p<0.001) improved from baseline to follow-up.

Conclusions

Fractional CO₂ laser treatment for breast cancer survivors is feasible and appears to reduce GSM symptoms across treatment and follow-up.

The effect of vaginal microablative fractional CO₂ laser treatment on vaginal cytology

Takacs P¹, Sipos AG², Kozma B², Cunningham TD³,
Larson K¹, Lampé R², Poka R²

1: Eastern Virginia Medical School, Norfolk, VA - USA. 2: University of Debrecen, Debrecen - Hungary.
3: The Center for Health Analytics and Discovery, Norfolk, VA - USA.



Abstract

Background and Objectives

Most recently vaginal laser treatment was introduced as a new option for women with genitourinary syndrome of menopause, vaginal dryness. Our objective was to assess the effects of intravaginal CO₂ laser treatment on vaginal cytology.

Study Design/Materials and Methods

Fifty-two women with symptoms of vaginal dryness were enrolled and underwent vaginal laser treatment using a fractional CO₂ laser. Patients received three vaginal laser treatments 4 weeks apart. Vaginal cytology was obtained before the first treatment and 4 weeks after each additional treatment. Vaginal dryness was assessed by using a Visual Analog Scale (VAS).

Results

Out of the 52 women enrolled, 34 were in menopause. Postmenopausal women had significantly lower vaginal maturation values (VMV) compared with premenopausal women at the baseline visit (mean \pm standard deviation [SD], 42 ± 23 vs. 68 ± 13 , $P < 0.01$). The vaginal dryness VAS was higher (worse) in postmenopausal women compared with premenopausal cases (mean \pm SD, 5.7 ± 4 vs. 2.4 ± 3 , $P < 0.01$). The VMV did not change significantly over time after vaginal laser treatment. However vaginal dryness VAS improved significantly after each treatment. Both in the premenopausal and postmenopausal groups, vaginal dryness scores improved significantly from baseline after the three treatments (postmenopausal 5.7 ± 4 vs. 1.6 ± 2.5 , $P < 0.01$ and premenopausal 2.4 ± 3 vs. 0.2 ± 0.5 , $P < 0.01$). Those patients who had improvement in VMV had significantly better (lower) dryness VAS compared with those women without an improvement in VMV after the three treatments (mean \pm SD, 0.3 ± 0.8 vs. 1.6 ± 2.6 , $P = 0.04$).

Conclusions

Vaginal dryness VAS improved significantly in a cohort of premenopausal and postmenopausal women undergoing vaginal CO₂ laser treatment despite no significant change in vaginal cytology.

Effect of rescue fractional microablative CO₂ laser on symptoms and sexual dysfunction in women affected by vulvar lichen sclerosis resistant to long-term use of topic corticosteroid: A prospective longitudinal study

Pagano T¹, Conforti A¹, Buonfantino C¹, Schettini F¹, Vallone R¹, Gallo A¹, Avino L¹, Alviggi C¹, De Placido G¹, Sopracordevole F²

1: University of Naples Federico II, Naples - Italy. 2: Centro di Riferimento Oncologico-National Cancer Institute, Aviano - Italy.



Abstract

Objective

The objective of this study was to evaluate the efficacy of rescue fractional microablative CO₂ laser treatment in women with severe symptoms and sexual dysfunction related to lichen sclerosis not responsive to long-term ultra-potent topical corticosteroid treatment.

Method

Consecutive eligible women with lichen sclerosis referred to our unit who received fractional microablative CO₂ laser treatment after failure of ultra-potent topical corticosteroid treatment were enrolled in the study. The diagnosis was confirmed by histological assessment in all cases. Patients underwent two cycles of CO₂ laser every 30 to 40 days. The severity of lichen sclerosis-related symptoms, sexual function, and procedure discomfort were evaluated with a visual analog scale in the same individual at baseline, after completion of each treatment cycle. Follow-up visits were scheduled during each treatment cycle and at least 1 month after completion of the treatment. The Friedman ANOVA test was used to evaluate differences in the visual analog scale scores of each symptom during treatment.

Results

A total of 100 patients with vulvar lichen sclerosis were screened, 40 of whom fulfilled the eligibility criteria. We found a significant improvement in vulvar itching ($\chi^2=31,182$, $P<0.001$), vulvar dryness ($\chi^2=40,364$, $P<0.001$), superficial dyspareunia ($\chi^2=37,488$, $P<0.001$), and sensitivity during intercourse ($\chi^2=22,143$, $P<0.001$) after two CO₂ laser cycles. Pain related to probe movement and laser application was low and did not change significantly consequent to treatment. No systemic or local adverse effects occurred during or after laser treatment.

Conclusions

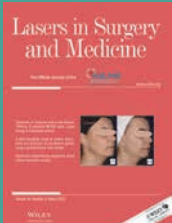Fractional microablative CO₂ laser treatment is safe and might represent an effective rescue procedure for patients suffering from lichen sclerosis who fail to respond to long-term ultra-potent topical corticosteroid treatment. These preliminary findings require further study with adequately powered randomized controlled trials.

Lasers in Surgery and Medicine - Epub 2020 Jan 28

Efficacy of fractional CO₂ laser, promestriene, and vaginal lubricant in the treatment of urinary symptoms in postmenopausal women: a randomized clinical trial

Aguiar LB¹, Politano CA¹, Costa-Paiva L¹, Juliato CRT¹

¹: State University of Campinas, Campinas, São Paulo - Brazil.



Abstract

Background and Objectives

Evaluating the efficacy of the fractional CO₂ laser, promestriene, and vaginal lubricant to treat urinary symptoms in women with genitourinary syndrome of menopause.

Study Design/Materials and Methods

We conducted a randomized clinical trial with 72 postmenopausal women aged 50 years or older. The participants were randomized to one intervention each in three treatment groups fractional CO₂ laser, promestriene, and vaginal lubricant. Urinary symptoms were assessed prior to treatment and 2 weeks after treatment completion using validated questionnaires, the International Consultation on Incontinence Questionnaire (ICIQ-UI SF), and the International Consultation on Incontinence Questionnaire Overactive Bladder (ICIQ-OAB).

Results

There was a significant reduction in the total ICIQ-UI SF score in the intragroup comparison (baseline vs. week 14) of the CO₂ laser group ($P=0.004$). This group also showed a statistically significant reduction in nocturia (1.33 ± 0.87 vs. 1.00 ± 0.76 , respectively; $P=0.031$). In the intergroup comparison after treatment, nocturia in the lubricant group had worsened compared with that of the other two groups ($P=0.002$). Regarding the total ICIQ-OAB score, the results of the CO₂ laser group were superior to those of the lubricant group in the intergroup comparison (7.76 ± 3.36 , $P=0.020$; analysis of variance $P=0.038$).

Conclusions

The results were significantly different between the intravaginal fractional CO₂ laser and topical estrogen groups for treating urinary symptoms related to the genitourinary syndrome of menopause. Further controlled and randomized studies are needed.



Journal of Lower Genital Tract Disease - Epub 2020 Feb 14

Fractionated CO₂ laser as therapy in recalcitrant lichen sclerosis

Balchander D¹, Nyirjesy P

1: Drexel University College of Medicine, Philadelphia, PA - USA.

Abstract

Objectives

The aim of this study was to evaluate the efficacy of the fractionated CO₂ laser in treating recalcitrant lichen sclerosis (LS).

Study Design

The study population was 40 women diagnosed with LS who were symptomatic despite medical treatment. Patients had at least 2 or more laser sessions with a 2-month follow-up visit at the Drexel Vaginitis Center. A fractionated CO₂ laser was used on affected areas at mild or standard power settings. Analyses were performed of changes in symptom rating scales, verbal reports, and physical examination findings.

Results

In the LS cohort of 40 patients, 22 women (55%) experienced symptoms that had persisted longer than 5 years before treatment. After the appropriate laser sessions, 72.5% of women described their improvement as significant or more than 66% improvement. In addition, there was a statistically significant reduction in vaginal pain, itching, dyspareunia, and dysuria. The presence of white epithelium decreased 20% after treatment. Furthermore, the mean corticosteroid use declined from 4.28 times per week to 2.04 times per week, indicating a resolution of many symptoms.

Conclusions

The fractionated CO₂ laser may be a helpful approach for managing LS that is unresponsive to traditional treatment options.

Response letter to comments related to "The effect of microablative fractional CO₂ laser on vaginal flora of postmenopausal women"

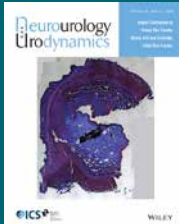Athanasίου S¹, Pitsouni E^{1,2}, Antonopoulou S³, Zacharakis D¹,
Salvatore S⁴, Falagas ME^{2,5,6}, Grigoriadis T¹

1: Alexandra Hospital, National and Kapodistrian University of Athens, Athens - Greece.

2: Alpha Institute of Biomedical Sciences, Athens - Greece. 3: G. Gennimatas General Hospital, Athens - Greece.

4: San Raffaele Hospital, Milan - Italy. 5: Henry Dynant Hospital Center, Athens - Greece.

6: Tufts University School of Medicine, Boston, MA - USA.



Abstract

Objectives

To assess the effect of microablative fractional CO₂ laser (MFCO2-Laser) therapy on the vaginal microenvironment of postmenopausal women.

Methods

Three laser therapies at monthly intervals were applied in postmenopausal women with moderate to severe symptoms of genitourinary syndrome of menopause, pH of vaginal fluid >4.5 and superficial epithelial cells on vaginal smear <5%. Vaginal fluid pH values, fresh wet mount microscopy, Gram stain and aerobic and anaerobic cultures were evaluated at baseline and 1 month after each subsequent therapy. Nugent score and Hay-Ison criteria were used to evaluate vaginal flora.

Results

Fifty-three women (mean age 57.2 ± 5.4 years) participated and completed this study. MFCO2-Laser therapy increased Lactobacillus (p < 0.001) and normal flora (p < 0.001) after the completion of the therapeutic protocol, which decreased vaginal pH from a mean of 5.5 ± 0.8 (initial value) to 4.7 ± 0.5 (p < 0.001). The prevalence of Lactobacillus changed from 30% initially to 79% after the last treatment. Clinical signs and symptoms of bacterial vaginosis, aerobic vaginitis or candidiasis did not appear in any participant.

Conclusion

MFCO₂-Laser therapy is a promising treatment for improving the vaginal health of postmenopausal women by helping repopulate the vagina with normally existing Lactobacillus species and reconstituting the normal flora to premenopausal status.


Keywords

UTIs; Vaginal atrophy; dyspareunia; intravaginal therapy; menopause; urinary tract infections; urogenital infections; vaginitis.

Effectiveness of CO₂ laser on urogenital syndrome in women with a previous gynecological neoplasia: A multicentric study

Angioli R¹, Stefano S², Filippini M³, Annalisa Pieralli A⁴,
Montera R¹, Plotti F¹, Gatti A¹, Bartolone M¹, Luvero D¹

1: University Campus Biomedico, Rome - Italy. 2: San Raffaele Hospital, Milan, - Italy.
3: Hospital State of Republic of San Marino, San Marino - Republic of San Marino. 4: Careggi University Hospital, Florence - Italy.



Abstract

Background

Many women diagnosed with gynecological cancers undergo adjuvant therapy, which may lead to transient or permanent menopause that ultimately leads to urogenital syndrome and vulvovaginal atrophy. Studies advise against the use of estrogen in women with a history of hormone-dependent cancer. One alternative is vaginal microablative fractional CO₂ laser, which promotes tissue regeneration through the production of collagen and elastic fibers.

Objective

To evaluate the effectiveness of CO₂ laser in the treatment of urogenital syndrome-in particular, symptomatic vulvovaginal atrophy in women who have survived gynecological cancers.

Methods

A retrospective study was carried out, including all patients with a history of gynecological cancers and vulvovaginal atrophy who underwent CO₂ laser treatment between November 2012 and February 2018 in four Italian centers. The study was approved by the local ethics committee of each participating institution. The inclusion criteria were women aged between 18 and 75; Eastern Cooperative Oncology Group performance status <2; and history of breast, ovarian, cervical, or uterus cancer. Patients had to have vulvovaginal atrophy and at least one of the following symptoms of urogenital syndrome: vaginal dryness, dyspareunia, vaginal introitus pain, burning, or itching. Three applications were administered at baseline, 30 days, and 60 days. All patients were evaluated before the first laser session, at each session, and 4 weeks after the last session. In particular, patients were asked to indicate the intensity of symptoms before the first session and 4 weeks after the last session, using Visual Analog Scale (VAS) scoring from 0 ('no discomfort') to 10 ('maximum discomfort').

Results

A total of 1213 patients underwent CO₂ laser treatment and of these, 1048 were excluded because they did not meet the inclusion criteria in the analysis. Finally, a total of 165 patients were included in the study. The mean age at the time of treatment was 53 years (range 31-73). Dryness improved by 66%, dyspareunia improved by 59%, burning improved by 66%, pain at introitus improved by 54%, and itching improved by 54%. The side effects were evaluated as pain greater than VAS score 6 during and after the treatment period. No side effects were seen in any sessions.

Conclusions

Fractional microablative CO₂ laser therapy offers an effective strategy in the management of the symptoms of genitourinary syndrome in post-menopausal women and in survivors of gynecological cancer.

Results

A total of 1213 patients underwent CO₂ laser treatment and of these, 1048 were excluded because they did not meet the inclusion criteria in the analysis. Finally, a total of 165 patients were included in the study. The mean age at the time of treatment was 53 years (range 31-73). Dryness improved by 66%, dyspareunia improved by 59%, burning improved by 66%, pain at introitus improved by 54%, and itching improved by 54%. The side effects were evaluated as pain greater than VAS score 6 during and after the treatment period. No side effects were seen in any sessions.

Conclusions

Fractional microablative CO₂ laser therapy offers an effective strategy in the management of the symptoms of genitourinary syndrome in post-menopausal women and in survivors of gynecological cancer.

Journal of Family and Reproductive Health - 2020 Jun

Fractional CO₂ Laser for Treatment of Vulvovaginal Atrophy: A Short Time Follow-up

Ghanbari Z¹, Sohbaty S², Eftekhar T¹, Sahebi L³,
Darvish S¹, Alasiri S¹, Pasikhani MD¹

1: Tehran University of Medical Science, Tehran - Iran. 2: Kerman University of Medical Sciences, Kerman - Iran.
3: Tabriz University of Medical Sciences, Tabriz - Iran.



Abstract

Objectives

The aim of this study was to evaluate the safety and efficacy of fractional CO₂ laser for treatment of vulvovaginal atrophy.

Materials and Methods

Evaluated the laser effect on vulvovaginal atrophy in 47 women aged 43-80 years. Each woman was treated with fractional CO₂ laser, SmartXide2 V²LR, DEKA, Monalisa Touch, vaginal 360° probe and cosmetic probe. The severity of vulvovaginal atrophy symptoms was evaluated before first session of laser and every 4 weeks after laser treatment until 12 weeks. Adverse effects including pain and itching were assessed at all visits. The statistical analysis was performed using SPSS version 23.

Results

The response to laser therapy for vaginal dryness was significantly ($p < 0.001$) improved. Also, the response to laser therapy for each symptom include dyspareunia, vaginal discharge, itching and urge urinary incontinence was statistically significant ($p < 0.001$) based on visual analogue scale (VAS).

Conclusions

It seems vaginal fractional CO₂ laser can be applied as an effective and safe treatment method in genitourinary syndrome of menopause (GSM). It is necessary to conduct studies with long-term follow-up.

American Journal of Obstetrics and Gynecology - Epub 2020 Jun 17

A cost-effectiveness analysis of vaginal carbon dioxide laser therapy compared with standard medical therapies for genitourinary syndrome of menopause-associated dyspareunia

Wallace SL, St Martin B, Lee K, Sokol ER

Stanford University Hospital, Palo Alto, CA - USA.



Abstract

Background

Topical vaginal estrogen therapy is considered the gold standard treatment for genitourinary syndrome of menopause-associated dyspareunia, but early investigations of energy-based devices show promise for patients with contraindications or those who are refractory to vaginal estrogen cream therapy. Although evaluating safety, efficacy, and long-term outcomes for novel technologies is critically important when new technologies become available to treat unmet healthcare needs, evaluation of the costs of these new technologies compared with existing therapies is also critically important but often understudied.

Objective

We sought to perform a cost-effectiveness analysis of 3 therapies for genitourinary syndrome of menopause, including vaginal estrogen therapy, oral ospemifene therapy, and vaginal CO₂ laser therapy and determine if vaginal laser therapy is a cost-effective treatment strategy for dyspareunia associated with genitourinary syndrome of menopause.

Study Design

An institutional review board-exempt cost-effectiveness analysis was performed by constructing a decision tree using decision analysis software (TreeAge Pro; TreeAge Software, Inc, Williamstown, MA) using integrated empirical data from the published literature. Tornado plots and 1-way and 2-way sensitivity analyses were performed to assess how changes in the model's input parameters altered the overall outcome of the cost-effectiveness analysis model.

Results

All 3 treatment methods were found to be cost-effective below the willingness-to-pay threshold of \$50,000.00 per quality-adjusted life year for moderate dyspareunia. The incremental cost-effectiveness ratio for vaginal CO₂ laser therapy was \$16,372.01 and the incremental cost-effectiveness ratio for ospemifene therapy was \$5711.14. Although all 3 treatment strategies were on the efficient frontier, vaginal CO₂ laser therapy was the optimal treatment strategy with the highest effectiveness. In a 1-way sensitivity analysis of treatment adherence, vaginal CO₂ laser therapy was no longer cost-effective when the adherence fell below 38.8%. Vaginal estrogen cream and ospemifene therapies remained cost-effective treatment strategies at all ranges of adherence. When varying the adherence to 100% for all strategies, oral ospemifene therapy was "dominated" by both vaginal CO₂ laser therapy and vaginal estrogen cream therapy. In a 2-way sensitivity analysis of vaginal CO₂ laser therapy adherence and vaginal CO₂ laser therapy cost, vaginal CO₂ laser therapy still remained the optimal treatment strategy at 200% of its current cost (\$5554.00) when the adherence was >55%. When the cost fell to 20% of its current cost (\$555.40), it was the optimal treatment strategy at all adherence values above 29%.

Conclusions

This study showed that vaginal fractional CO₂ laser therapy is a cost-effective treatment strategy for dyspareunia associated with GSM, as are both vaginal estrogen and oral ospemifene therapies. In our model, vaginal CO₂ laser therapy is the optimal cost-effective treatment strategy, and insurance coverage should be considered for this treatment option if it is proven to be safe and effective in FDA trials.



Lasers in Medical Science - Epub 2020 Jun 21

The effect of the CO₂ fractional laser or premarin vaginal cream on improving sexual function in menopausal women: a randomized controlled trial

Eftekhar T, Forooghifar T, Khalili T, Shariat M, Haghollahi F

Tehran University of Medical Sciences, Tehran - Iran.

Abstract

Introduction

Sexual dysfunction is a complex problem in postmenopausal women with a prevalence rate of 68%-86%. This study aimed to evaluate the effect of a fractional CO₂ laser or vaginal cream on the improvement of sexual function in menopausal women.

Methods

This is a two-group clinical trial study. Postmenopausal women with the inclusion criterion were enrolled and randomly divided into 2 groups of intervention (n=25) and control group (n=25). In the intervention group, CO₂ laser therapy was performed every month for three months, and in the control group, Premarin vaginal cream was applied (0.625 mg, 3 nights a week for 3 months). Vaginal health index (VHI) scoring and Female Sexual Function Index (FSFI) questionnaires were completed before and three months after the treatment.

Results

The effects of the laser treatment were greater than the Premarin group with respect to improvement in sexual desire, orgasms, sexual satisfaction, less pain during sexual relations, and overall sexual function (P <0.05).

Conclusion

It seems that the fractional CO₂ laser may be more effective than hormonal therapy in improving sexual function in postmenopausal women.

Lasers in Surgery and Medicine – Epub 2020 Aug 14

Fractional microablative CO₂ laser-related histological changes on vulvar tissue in patients with genitourinary syndrome of menopause

Pagano T¹, Travaglino A¹, Raffone A¹, Vallone R¹, Buonfantino C¹, De Rosa P¹, Locci M¹, Guadagno E¹, Insabato L¹, Salvatore S², De Placido G¹

1: University of Naples Federico II, Naples - Italy. 2: San Raffaele Hospital, Milan - Italy.



Abstract

Background and objectives

Fractional CO₂ laser has been proposed as an effective treatment for the genitourinary syndrome of menopause (GSM). However, the effects of laser treatment on vulvar tissue have never been assessed. We aimed to assess histological changes related to fractional CO₂ laser in vulvar tissue from GSM patients.

Study Design/Materials and Methods

A single-center observational prospective cohort study was performed enrolling all GSM patients from July 2017 to October 2018. Patients underwent three outpatient vulvovaginal applications of fractional CO₂ laser and vulvar biopsy before and after treatment. Rates of histological changes in vulvar tissue, the difference in means of Vulva Health Index (VuHI), Vaginal Health Index (VHI), Visual Analogue Scale scores for GSM symptoms, and procedure-related pain, and rate of patient's overall satisfaction with treatment were assessed. Univariate comparisons between continuous variables were performed by using the paired t-test (α error = 0.05).

Results

Of 20 enrolled patients, 18 underwent all laser applications, and 15 underwent both vulvar biopsies. 93.3% of patients showed remodeling of vulvar connective tissue; 80% showed improvement in vulvar epithelium trophism and 86.7% showed neovascularization. Differences in means between before and after treatment were significant for VuHI, VHI, and all GSM symptoms. Means \pm standard deviation of the degree of pain at each laser application were 4.4 ± 0.9 , 3.7 ± 1.6 , and 2.9 ± 1.9 . The rate of overall satisfaction with the treatment was 72.2%.

Conclusion

Fractional CO₂ laser leads to a restoration of the normal architecture of vulvar tissue, with significant improvement in GSM-related signs and symptoms, and overall satisfaction with the treatment in most GSM patients.

Menopause – Vol.27, No.8, 2020

Treatment for vaginal atrophy using microablative fractional CO₂ laser: A randomized double-blinded sham-controlled trial

Ruanphoo P, Bunyavejchevin S

Chulalongkorn University, Bangkok, - Thailand.



Abstract

Objective

The aim of this study was to evaluate the efficacy of vaginal CO₂ laser for the treatment of vaginal atrophy compared to the sham procedure.

Methods

Between June 2016 and May 2017, postmenopausal women with moderate to severe intensity of any vaginal atrophy symptoms (VAS) were invited to participate in the study. A total of 88 women were randomized to receive treatment with either vaginal CO₂ laser or sham procedures every 4 weeks for three sessions. Both the participants and the evaluators were blinded to the treatment. Vaginal Health Index (VHI) score (primary outcome), VAS score, and the item for vaginal dryness from the International Consultation on Incontinence Modular Questionnaire-Vaginal Symptoms questionnaire were compared between the two groups by intention-to-treat analysis at 12 weeks after treatment.

Results

Eighty-eight women were enrolled into the study and nine women were lost to follow-up. After 12 weeks of laser treatment, the VHI, VAS, and International Consultation on Incontinence Modular Questionnaire-Vaginal Symptoms (item for vaginal dryness) scores were significantly improved. For VHI and VAS scores the mean difference between the laser group versus the sham group was 1.37 (95% CI: 0.12-2.63), $P < 0.001$ and -1.52 (95% CI: -2.21 to -0.82), $P = 0.03$, respectively.


Conclusion

This study demonstrated that the application of microablative fractional CO₂ laser was effective in treating vaginal atrophy. It could be a promising alternative treatment for postmenopausal women with vaginal atrophy.

CO₂ laser and the genitourinary syndrome of menopause: A randomized sham-controlled trial

Salvatore S¹, Pitsouni E², Grigoriadis T², Zacharakis D²,
Pantaleo G³, Candiani M¹, Athanasiou S²

1: San Raffaele Hospital, Milan - Italy. 2: Alexandra Hospital, National and Kapodistrian University of Athens, Athens - Greece.
3: Vita-Salute San Raffaele University, Milan - Italy.



Abstract

Purpose

This study aimed to clarify the efficacy of intravaginal CO₂-laser treatment in postmenopausal women with genitourinary syndrome of menopause (GSM).

Materials and Methods

This double-blind, randomized, sham-controlled trial included postmenopausal women diagnosed with GSM and bothersome dryness and dyspareunia. Treatment consisted of three sessions. Active CO₂-laser treatments (active group) were compared to sham treatments (sham group) with the primary endpoints being changes in dryness and dyspareunia intensity, as assessed by the 10-cm visual analog scale. Secondary endpoints were as follows: changes in Female Sexual Function Index (FSFI; total score and all domains), itching, burning, dysuria, and Urogenital Distress Inventory (UDI-6); incidence of symptoms; and presence of adverse events. All outcomes were evaluated at baseline and 4 months post baseline.

Results

Fifty-eight women (28 in the active group and 30 in the sham group) were eligible for inclusion. In the active group, dryness, dyspareunia, FSFI (total score), itching, burning, dysuria, and UDI-6 were significantly improved (mean [standard deviation] -5.6 [2.8], -6 [2.6], 12.3 [8.9], -2.9 [2.8], -2.3 [2.8], -0.9 [2.1], and -8.0 [15.3], respectively). In the sham group, dryness, itching, and burning were significantly improved (-1.9 [2], -1.4 [1.9], and -1 [1.9], respectively). All changes were in favor of the active group. After completion of the protocol, the proportion of participants with dryness, dyspareunia, and sexual dysfunction was significantly lower in the active group compared to those in the sham group (all $p < 0.005$).

Conclusion

CO₂ laser could be proposed as an effective alternative treatment for the management of GSM as it is superior to sham treatments.

Evaluation of the efficacy of fractional CO₂ laser in the treatment of vulvar and vaginal menopausal symptoms

Sindou-Faurie T¹, Louis-Vahdat C², Oueld Es Cheikh E¹,
Canlorbe G¹, Mergui JL¹, Uzan C¹, Azaïs H¹

1: University Hospital Pitié Salpêtrière-Charles Foix, Paris - France. 2: Private Office, Paris - France.



Abstract

Purpose

The objective of this study was to evaluate the efficacy of fractional CO₂ laser to manage vulvar and vaginal symptoms of Genitourinary Syndrome of Menopause (GSM) in postmenopausal women.

Methods

All postmenopausal women with symptoms of GSM undergoing fractional CO₂ laser treatment in our centers were asked to fill out a validated quality of life questionnaire (Global Quality of Life Questionnaire), Visual Analog Scale (VAS) for symptoms, a questionnaire on overall discomfort related to pelvic floor symptoms, and the Female Sexual Function Index (FSFI) at several points: before each session (three sessions at monthly intervals) and one 3 months after treatment completion. Statistical analysis compared pre-therapy data and data at 3 months of treatment.

Results

Forty-six women were included with a mean age of 57.3 years (\pm 11.1 years). A significant improvement was demonstrated in vaginal dryness ($p = 6.34 \cdot 10^{-6}$) and for symptoms of stress urinary incontinence ($p = 0.043$). Among sexually active patients, there was a significant improvement in the degree of symptom discomfort affecting their satisfaction ($p = 0.007$), dyspareunia ($p = 0.001$) and sensitivity during sexual intercourse ($p = 0.001$). Significantly, more women were able to achieve ($p = 0.026$) and maintain ($p = 0.018$) lubrication during intercourse.

Conclusion

CO₂ laser treatment seems to improve the quality of life and sexual health of patients as well as GSM symptoms at 3 months of treatment; long-term reevaluation is necessary to demonstrate that improvement persists over time.

The Fractional CO₂ Laser for the Treatment of Genitourinary Syndrome of Menopause: A Prospective Multicenter Cohort Study

Li J¹, Li H², Zhou Y³, Xie M⁴, Miao Y⁵, Wang L⁶,
Zhao Y⁷, Ying T⁸, Hu Y², Chen Y³, Chen Y⁴, Sun X¹, Wang J¹

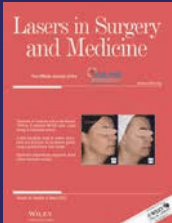1: Peking University People's Hospital, Beijing - China. 2: Peking University Shenzhen Hospital, Shenzhen - China.

3: Changsha Hospital for Maternity and Child Healthcare, Changsha - China.

4: Sun Yat-sen Memorial Hospital of Sun Yat-sen University, Guangzhou - China. 5: West China Second University Hospital, Chengdu - China.

6: The Third Affiliated Hospital of Zhengzhou University, Zhengzhou - China. 7: Puyang Oilfield General Hospital, Puyang - China.

8: Maternity and Child Healthcare Hospital, Liuzhou - China.



Abstract

Background and objectives

This prospective multicenter cohort study aimed to compare the efficacy and safety of the fractional carbon dioxide (CO₂) laser with that of topical estrogen for vaginal treatment and relieving symptoms of genitourinary syndrome of menopause (GSM).

Materials and Methods

This study included 162 postmenopausal patients who received vaginal laser or topical Estriol cream therapy between January 2017 and May 2019 at eight study centers in China. The degree of GSM-related symptoms (vaginal burning, dryness, and dyspareunia) was evaluated using the Vaginal Health Index score (VHIS) and Visual Analog Scale (VAS) at baseline, 1, 3, 6, and 12 months posttreatment. The primary endpoint was the improvement in vaginal burning, dryness, and dyspareunia at 6 months after treatment. Multivariate logistic regression was used to compare the rate of improvement in the two groups.

Results

In the laser group, compared with baseline, significant differences were seen in the VHIS after the first or second treatment session and at 1, 3, 6, and 12 months posttreatment ($P < 0.01$). At 6 months after treatment, both laser and control group showed improvement in vaginal burning, vaginal dryness, and dyspareunia ($P > 0.05$). The VAS findings at 6 months posttreatment were significantly different when compared with the pretreatment findings ($P < 0.001$). There were no significant adverse effects in the two groups.


Conclusion

Fractional CO₂ laser vaginal treatment could be a safe and effective option for treating symptoms of GSM, including vaginal burning, dryness, and dyspareunia. The improvement in symptoms was comparable with that seen with topical estrogen therapy and lasted for at least 6–12 months posttreatment.

The beneficial effects of fractional CO₂ laser treatment on perineal changes during puerperium and breastfeeding period: A multicentric study

Luvero D¹, Filippini M², Salvatore S³,
Pieralli A⁴, Farinelli M², Angioli R¹

1: Campus Bio-Medico University, Rome - Italy. 2: Hospital State of Republic of San Marino, San Marino - Republic of San Marino.
3: San Raffaele Hospital, Milan - Italy. 4: Careggi University Hospital, Florence - Italy.



Abstract

Childbirth is a great change in woman life because of hormonal, physical and psychological alterations that are associated with this process. Dyspareunia and perineal pain are commonly reported symptoms in the postpartum period, mainly due to perineal trauma, lacerations, episiotomy, and forceps or vacuum use at delivery. Among non-pharmacological treatment, a new trend is gaining popularity, which is the energy-based therapy, including fractional micro-ablative CO₂ laser. We conducted a multicentric retrospective study to assess the efficacy and the possible side effects of CO₂ laser treatment on transient vulvovaginal atrophy and perineal postpartum pain related to puerperium and breastfeeding period. All patients were submitted to 3 or 4 sessions of CO₂ laser treatment. As per protocol, an initial, intermediate (after 2 sessions) and final (3 months after the last cycle) evaluation of the symptoms were made, using a VAS (Visual Analogue Scale 0-10). We also compared this group of patients with a control group with no treatment. At the final evaluation, patients showed a significant improvement for dyspareunia (VAS from 7.95 to 3.14, $p < 0.0001$). A significant improvement was also registered in pain at the vaginal orifice (VAS from 6.94 to 2.05, $p = 0.0001$), dryness (VAS from 6.6 to 2.9, $p = 0.0022$), itching (VAS from 4.5 to 1.16, $p = 0.0053$), heat (VAS from 3 to 0, $p = 0.0119$) and burning (VAS from 5.5 to 1.6, $p = 0.0013$) if compared with the control group. Quality of life for the women during the breastfeeding and puerperium is important and training is mandatory to avoid side effects in order to improve the CO₂ laser performance.

The short-term efficacy and safety of fractional CO₂ laser therapy for vulvovaginal symptoms in menopause, breast cancer, and lichen sclerosis

Gardner AN^{1,2}, Aschkenazi SO²

1: UT Health San Antonio, San Antonio, TX - USA. 2: Medical College of Wisconsin, Waukesha, WI - USA



Abstract

Objectives

To review the short-term effects and safety of vulvovaginal fractional microablative CO₂ laser therapy on atrophy symptoms using validated questionnaires pre- and posttreatment.

Materials and Methods

Retrospective chart review 139 women with vulvovaginal atrophy symptoms, who completed three treatments about 6 weeks apart. All were >18 years old and non-pregnant. As is the practice in our clinic for all women receiving treatment, they were surveyed prior to the 1st and 3rd treatments with validated questionnaires, Female Sexual Function Index (FSFI) and Vulvovaginal Symptoms Questionnaire (VSQ), as well as a visual analog scale (VAS). Paired t test was completed on the pre- and post FSFI and VAS scores. Pre- and postproportions of the VSQ were evaluated by the Fisher's exact test. Means were presented for each study variable. Multivariable regression analysis was completed on continuous and binomial variables for scores predictors.

Results

Mean age was 62 years with a mean follow-up of 13.8 weeks. Concomitant topical estrogen was reported in 53% (n = 74). Breast cancer diagnosis was documented in 27% (n = 38), and lichen sclerosis in 22% (n = 31). All FSFI scores improved (pre: 12.7, post: 19.0, P < 0.001). The VSQ showed 18 of 21 questions significantly improved (P < 0.05). The VAS showed significant improvement in painful intercourse (pre: 6.6, post: 2.4, P < 0.001), and vulvar dryness (pre: 4.6, post: 1.5, P < 0.001). Posttreatments, 17 additional women became sexually active. No major adverse events were reported.

Conclusion

Fractional CO₂ laser may be effective and safe for the treatment vulvovaginal atrophy.

Patient-reported sexual function of breast cancer survivors with genitourinary syndrome of menopause after fractional CO₂ laser therapy

Quick AM¹, Zvinovski F¹, Hudson C¹, Hundley A¹, Evans C¹, Stephens JA², Arthur E¹, Ramaswamy B¹, Reinbolt RE¹, Noonan AM¹, VanDeusen JB¹, Wesolowski R¹, Stover DG¹, Williams NO¹, Sardesai SD¹, Faubion SS³, Loprinzi CL⁴, Lustberg MB¹

1: The Ohio State University Medical Center, Columbus, OH - USA. 2: The Ohio State University College of Medicine, Columbus, OH - USA. 3: Mayo Clinic, Jacksonville, FL - USA. 4: Mayo Clinic, Rochester, MN - USA.



Abstract

Objectives

The objective of this pilot study was to evaluate the change in sexual function following treatment with fractional CO₂ laser therapy in breast cancer (BC) survivors with genitourinary syndrome of menopause (GSM).

Materials and Methods

A single-arm feasibility study of BC survivors with symptoms of GSM, including dyspareunia and/or vaginal dryness, was conducted. Participants who received three treatments with fractional CO₂ laser and 4-week follow-up were contacted for patient-reported outcomes and adverse events at 12 months. Sexual function was measured using the Female Sexual Function Index (FSFI) and Female Sexual Distress Scale Revised (FSDS-R). Descriptive statistics were calculated for patient demographics and disease characteristics for the set of participants who agreed to long-term follow-up and those who were lost to follow-up. FSFI and FSDS-R scores were summarized at baseline, 4 weeks and 12 months, as well as the change from baseline, and were compared using a Wilcoxon signed rank test.

Results

A total of 67 BC survivors enrolled, 59 completed treatments and 4-week follow-up; 39 participated in the 12 month follow-up. The overall FSFI score improved from baseline to 4-week follow-up (median Δ 8.8 [Q1, Q3] (QS) (2.2, 16.7)), $P < 0.001$). There were improvements at 4 weeks in all domains of the FSFI ($P < 0.001$ for each) including desire (median Δ 1.2; QS [0.6, 1.8]), arousal (median Δ 1.2; QS [0.3, 2.7]), lubrication (median Δ 1.8 (0, 3.3), orgasm (median Δ 1.2; QS [0, 3.6]), satisfaction (median Δ 1.6 (0.4, 3.2)), and pain (median Δ 1.6 (0, 3.6)). The FSDS-R score also improved from baseline to 4-week follow-up (median Δ -10.0; QS [-16, -5] $P < 0.001$) indicating less sexually related distress. The scores of the FSFI and FSDS-R remained improved at 12 months and there were no serious adverse events reported.

Conclusion


In BC survivors with GSM, the total and individual domain scores of the FSFI and the FSDS-R improved after fractional CO₂ laser therapy.

Breast Cancer Research and Treatment - Epub 2021 Mar 16

Fractional CO₂ vaginal laser for the genitourinary syndrome of menopause in breast cancer survivors

Siliquini GP¹, Bounous VE^{2,3}, Novara L², Giorgi M², Bert F³, Biglia N³

1: SedesSapientiae Institute, Turin - Italy. 2: Umberto I Hospital, University of Turin, Turin - Italy.
3: Department of Public Health, University of Turin, Turin - Italy.



Abstract

Adjuvant chemotherapy and endocrine therapy can induce early iatrogenic menopause or worsen pre-existing menopausal symptoms in breast cancer survivors (BCS). The second most frequent menopausal symptom after hot flushes is the genitourinary syndrome (GSM). Since hormone replacement therapy is contraindicated in BCS, vaginal laser might represent a new nonhormonal option for GSM. This study aims at evaluating the effectiveness of the fractional CO₂ vaginal laser for GSM in BCS compared with healthy women. This is a retrospective study on 135 postmenopausal women (45 BCS and 90 healthy women) who underwent fractional CO₂ laser for GSM. Objective (VHI and VVHI) and subjective outcomes (VAS for dyspareunia and vaginal dryness and a pain questionnaire) were evaluated at baseline visit and at every follow-up visit. Subjective and objective parameters improved significantly in both groups after laser therapy. The improvement was progressive and long-lasting up to 12 months after the end of the treatment. No severe adverse events were observed during the treatment. Fractional CO₂ vaginal laser induces a significant and long-lasting improvement on GSM symptoms in BCS. However, this improvement is slower than in healthy women undergoing the same treatment. Laser therapy turns out to be safe and well-tolerated.

Keywords

breast cancer survivors; vaginal atrophy; vaginal laser.

Menopause - Epub 2021 May 17

Comparison of topical fractional CO₂ laser and vaginal estrogen for the treatment of genitourinary syndrome in postmenopausal women: a randomized controlled trial

Dutra PFSP¹, Heinke T², Pinho SC¹, Focchi GRA², Tso FK¹,
De Almeida BC³, Silva I¹, Speck NMG¹

1: Federal University of São Paulo - Paulista Medical School, Sao Paulo - Brazil.
2: Hospital das Clinicas, University of São Paulo, Sao Paulo - Brazil.



Abstract

Objectives

To compare the efficacy of fractional CO₂ laser therapy with topical estrogen therapy for the treatment of postmenopausal genitourinary syndrome of menopause.

Materials and Methods

We conducted a randomized controlled clinical trial involving 25 postmenopausal women. Participants were aged between 50 and 65 years with at least 1 year of amenorrhea and follicle-stimulating hormone levels of >40 IU/L. The women were randomized into two groups: the laser therapy group (n = 13) and the vaginal topical estrogen therapy group (n = 12). Changes in the vaginal epithelium thickness, Frost index, and cell maturation were analyzed in both the groups. The female sexual quotient of each woman was also evaluated. Subjective evaluation was performed through a physical examination.

Results

Histological analysis showed a significant increase in the vaginal epithelium thickness at the end of treatment in females in both the laser therapy (P < 0.001) and topical estrogen therapy (P = 0.001) groups. The topical estrogen therapy group tended to present a higher maturation index at the end of treatment when compared with that of the other group. Sexual function increased significantly over time in both the topical estrogen therapy (P < 0.001) and laser therapy (P < 0.001) groups. Subjective evaluation through physical examination showed a significant improvement in atrophy in both the groups.

Conclusion

Despite the nonequivalence with topical estrogen therapy, our data suggest that laser therapy is an effective method for the treatment of vulvovaginal atrophy.

Clobetasol Compared With Fractionated Carbon Dioxide Laser for Lichen Sclerosus: A Randomized Controlled Trial

Burkett LS¹, Siddique M, Zeymo A, Brunn EA, Gutman RE, Park AJ, Iglesias CB

¹: Magee-Womens Hospital, University of Pittsburgh Health System, Pittsburgh, PA - USA.

MedStar Washington Hospital Center and Georgetown University School of Medicine, Washington, DC - USA; Medstar Health Research Institute, Hyattsville, MD - USA; Magee-Womens Hospital, University of Pittsburgh Health System, PA - USA; Brown Women & Infants Hospital of Rhode Island, Providence, RI - USA; Cleveland Clinic, Cleveland, OH - USA.



Abstract

Objectives

To compare 6-month safety and efficacy outcomes of fractionated CO₂ laser (laser) with topical clobetasol propionate (steroid) for treatment of symptomatic vulvar lichen sclerosus.

Materials and Methods

We conducted a single-center randomized controlled trial that compared fractionated CO₂ laser with steroid treatment for patients with biopsy-proven lichen sclerosus. Randomization was stratified by prior clobetasol propionate use. The primary outcome was mean change in Skindex-29 score at 6 months. A total sample size of 52 participants were recruited to detect a mean difference of 16 points on the Skindex-29 (SD±22) with 80% power, based on a one-sided two-sample t test with $\alpha=0.05$, accounting for 10% attrition. Secondary outcomes included validated subjective and objective measures. Intention-to-treat, per protocol, and regression analysis based on prior steroid exposure were performed.

Results

202 women were screened, 52 were randomized, and 51 completed a 6-month follow-up. No significant difference was found in baseline demographics, symptoms, and physician assessment scores. There was greater improvement in the Skindex-29 score in the laser arm at 6-months (10.9 point effect size, 95% CI 3.42-18.41; $P=0.07$). Overall, 89% (23/27) of patients in the laser group rated symptoms as being "better or much better" compared with 62% (13/24) of patients in the steroid group, $P=.07$. More patients (81%, 21/27) were "satisfied or very satisfied" with laser treatment compared with steroid treatment (41%, 9/24); $P=.01$. After stratification for previous steroid use, the significant change of Skindex-29 score was only seen in the previously exposed group. There was one adverse event in each group: minor burning and blistering at the laser site and reactivation of genital herpes 1 week after starting steroid.

Conclusion

Fractionated CO₂ laser treatment showed significant improvement in subjective symptoms and objective measures compared with clobetasol propionate, without serious safety or adverse events at 6 months.

Fractional CO₂ laser treatment effect on cervicovaginal lavage zinc and copper levels: a prospective cohort study

Sipos AG¹, Pákozdy K¹, Jäger S², Larson K³, Takacs P³, Kozma B¹

1: University of Debrecen, Debrecen - Hungary. 2: Fempharma Ltd, Debrecen - Hungary. 3: Eastern Virginia Medical School, Norfolk, VA - USA.



Abstract

Objectives

To compare the efficacy of fractional CO₂ laser therapy with topical estrogen therapy for the treatment of postmenopausal genitourinary syndrome of menopause.

Materials and Methods

We conducted a randomized controlled clinical trial involving 25 postmenopausal women. Participants were aged between 50 and 65 years with at least 1 year of amenorrhea and follicle-stimulating hormone levels of >40 IU/L. The women were randomized into two groups: the laser therapy group (n = 13) and the vaginal topical estrogen therapy group (n = 12). Changes in the vaginal epithelium thickness, Frost index, and cell maturation were analyzed in both the groups. The female sexual quotient of each woman was also evaluated. Subjective evaluation was performed through a physical examination.

Results

Histological analysis showed a significant increase in the vaginal epithelium thickness at the end of treatment in females in both the laser therapy (P < 0.001) and topical estrogen therapy (P = 0.001) groups. The topical estrogen therapy group tended to present a higher maturation index at the end of treatment when compared with that of the other group. Sexual function increased significantly over time in both the topical estrogen therapy (P < 0.001) and laser therapy (P < 0.001) groups. Subjective evaluation through physical examination showed a significant improvement in atrophy in both the groups.

Conclusion

Despite the nonequivalence with topical estrogen therapy, our data suggest that laser therapy is an effective method for the treatment of vulvovaginal atrophy.

Conservative Management of Urinary Stress Incontinence in Selected Post Menopause Patients with Fractional CO₂ Laser

Tovar UM¹, Marco Antonio Tovar MA¹, Santillan-Romero A³, Pichardo-Rodríguez R³, Valladares-Garrido MJ², Grandez - Urbina JA², García - Perdomo H⁴

1: Private Clinic CIRUFEME, Lima - Peru. 2: Universidad Continental, Lima - Peru.
3: Universidad Ricardo Palma, Lima - Peru. 4: Universidad del Valle, Cali - Colombia.



Abstract

Objectives

This PUBA study aims to evaluate the effectiveness of the Fractional CO₂ Laser in the conservative treatment of Urinary Stress Incontinence in pre-selected Post-Menopausal Patients, with urine loss to Valsalva maneuvers.

Materials and Methods

Symptoms of Urinary Stress Incontinence were evaluated before, and 1 month after the last session (3 sessions with a 30-day interval between them) in 50 post-menopausal women (Middle Age - Menopause, Interquartile Range Parity - BMI). Subjective measures (ICIQ SF, VAS) and objective measures such as PAD TEST were used (a dry diaper was previously weighed, and she was instructed to take 500 cc for 15 minutes at rest, and then for 45 minutes to perform Valsalva maneuvers, go up and down stairs, sit, stand up, etc. and then reweigh the diaper) during the study period in order to evaluate the results of the fractional CO₂ laser treatment compared to the baseline.

Results

Of the 50 patients enrolled, 12 patients in total who presented minimal Urinary symptoms of incontinence (USI) according to the ICIQ questionnaire, all were cured, defining this, as the no loss of urine. Of the 18 patients who presented moderate USI, 10 were cured (55%), that is, they did not present urine loss, and the other 8 patients (45%) had partial recovery, but continued losing urine. Of the 20 patients who presented severe USI, none were cured, 9 (45%) of them remained in severity, and 11 (55%) patients had partial recovery, migrating to the degree of moderate USI. An objective assessment was also performed using the PAD TEST, of the 12 patients with minimal USI, all were cured, of the 18 patients who presented moderate USI, what was found in the ICIQ was confirmed, with 10 patients cured, and 8 with partial recovery. Likewise, of the 20 patients with severe USI, none were cured.

Conclusion

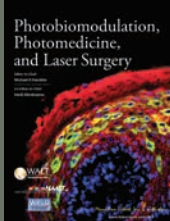
In the present study, the data suggest that Fractional CO₂ Laser is an effective alternative for the treatment of Minimal-Moderate Urinary Stress Incontinence in well-selected post-menopausal patients, with positive results that persist over time.

Photobiomodulation, Photomedicine and Laser Surgery - Epub 2021 Sept 21

Treatment of Rectovaginal Fistula Using Fractionate CO₂ Vaginal Laser: A Case Series

Drumond DG¹, De Góis Speck NM², Chebli JMF¹,
De Moraes Sarmento Condé C⁴, Chebli LA¹, Pannain GD¹, Esperança SD³

1: Federal University of Juiz de Fora, Juiz de Fora - Brazil. 2: Federal University of São Paulo, São Paulo - Brazil.
3: Hospital Israelita Albert Einstein, Sao Paulo - Brazil. 4: Radiologist.



Abstract

Objectives

To report five cases of patients with RVF submitted to intravaginal CO₂ fractional laser treatment, as a complementary and additional therapeutic option in this scenery.

Materials and Methods

Five laser sessions with monthly intervals followed by complete evaluation through clinical examination and magnetic resonance imaging of the pelvis were performed for all patients.

Results

Three patients had complete resolution of symptoms after the end of planned vaginal laser sessions, whereas two patients reported significant improvement in symptoms. Four patients who had stopped having sex due to their condition admitted to resuming regular sexual activity. In addition, all five patients had closure of the fistulous track confirmed by pelvic MRI. No adverse events from vaginal laser therapy were reported by any of the patients.

Conclusion

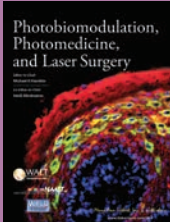
We believe this method to be a complementary, promising, and safe therapeutic alternative for the management of RVF. It may potentially enable return to regular sexual activity. Future studies using this therapeutic strategy are needed to confirm the efficacy and safety of this method in this clinical setting.

Photobiomodulation, Photomedicine and Laser Surgery - Epub 2021 Nov 10

Treatment of Vulvovaginal Atrophy with Fractional CO₂ Laser: Evaluating Real-World Data

Kiesel M¹, Wöckel A¹, Zeller C², Meden H²

1: University Hospital Würzburg, Würzburg - Germany, 2: Rütli Medical Center, Rütli - Switzerland.



Abstract

Objectives

To evaluate real-world data for the use of fractional CO₂ laser therapy for treating symptoms of vulvovaginal atrophy (VVA).

Materials and Methods

Thirty-six patients were treated in a single medical center. They consisted of pre- and postmenopausal women and received three fractional CO₂ laser therapy treatments with 3-6 weeks between each treatment. Each patient financed the treatment privately. The symptoms pain, pruritus, dyspareunia, burning, dryness, and dysuria were recorded with a visual analog scale (1-10) before the first, second, and third laser treatment. The data were examined retrospectively.

Results

Pain was reduced from a mean of 2.5 points (minimum 0, maximum 9 points) to 1.1 (minimum 0, maximum 8 points) before the third laser treatment. Pruritus showed a mean score of 3.8 (minimum 0, maximum 10 points). This decreased to 1.4 (minimum 0, maximum 8 points). Dyspareunia scored a mean of 6.8 (minimum 0, maximum 10 points). After two laser therapies, the score was 3.3 (minimum 0, maximum 8 points). Burning showed 4.2 points (minimum 0, maximum 10 points). Having experienced two laser therapy sessions, the patients scored 1.5 (minimum 0, maximum 9 points) points. The severity of dryness dropped from 6.5 (minimum 0, maximum 10 points) to 3.3 (minimum 0, maximum 9 points). Dysuria was stated with 1.8 points (minimum 0, maximum 10 points) before the first and 0.5 points (minimum 0, maximum 6 points) before the third laser therapy. All changes showed statistical significance ($p < 0.002$).

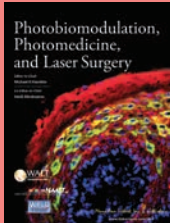
Conclusion

This real-world data propose fractional CO₂ laser to reduce VVA-associated genital discomfort, thus being a valuable therapy option for pre- and postmenopausal women.

Effects of fractional CO₂ laser treatment on patients affected by vulvar lichen sclerosis: a prospective study

Filippini M¹, Sozzi J¹, Farinelli M¹, Verdelli A²

1: State Hospital of Republic of San Marino, San Marino - Republic of San Marino. 2: Villa Donatello Clinic, Florence - Italy.



Abstract

Objectives

This is a prospective, single-center study aimed at evaluating the effect of fractional microablative CO₂ laser treatment on women affected by VLS.

Materials and Methods

Patients with histologically confirmed VLS underwent three fractional microablative CO₂ laser treatments, 4 weeks apart, on the genital affected areas. Clinical and VLS-related symptoms, side effects, and patient satisfaction index were assessed and recorded for all the patients using the visual analog scale (VAS).

Results

Data from a total of 70 patients were included, paired at different time points and analyzed. VLS-related symptoms and other relevant parameters (pH, vaginal introitus discomfort, dyspareunia, vaginal dryness, itching, and burning) showed a statistically significant improvement ($p < 0.001$) after the first laser treatment and kept improving after second and third sessions. According to VAS, the two most common symptoms, vaginal introitus discomfort and dyspareunia, went from (mean \pm standard deviation) 8.2 ± 2.3 and 8.3 ± 2.2 , respectively, at baseline, to 3.6 ± 2.6 and 3.8 ± 2.6 , respectively, 1 month after the last treatment. Vaginal dryness, itching, and burning were significantly improved as well. Most patients declared to be very satisfied with the results of the treatment. A total of 62.8% of the women expressed a satisfaction score ≥ 8 on a scale from 0 to 10.

Conclusion

Fractional microablative CO₂ laser treatment seems to be safe and effective to treat VLS and improve VLS-related symptoms.

Long-Term Follow-Up of Fractional CO₂ Laser Therapy for Genitourinary Syndrome of Menopause in Breast Cancer Survivors

Quick AM¹, Hundley A¹, Evans C¹, Stephens JA², Ramaswamy B², Reinbolt RE¹, Noonan AM¹, Van Deusen JB¹, Wesolowski R¹, Stover DG¹, Williams NO¹, Sardesai SD¹, Faubion SS³, Loprinzi CL⁴, Lustberg MB⁵

1: The Ohio State University Medical Center, Columbus, OH - USA. 2: The Ohio State University Center for Biostatistics, Columbus, OH - USA. 3: Mayo Clinic, Jacksonville, FL - USA. 4: Mayo Clinic, Rochester, MN - USA. 5: Yale Cancer Center, New Haven, CT - USA.



Abstract

Objectives

The objective of this study was to determine the long-term efficacy of fractional CO₂ laser therapy in breast cancer survivors.

Materials and Methods

This was a single-arm study of breast cancer survivors. Participants received three treatments of fractional CO₂ laser therapy and returned for a 4 week follow-up. Participants were contacted for follow-up at annual intervals. The Vaginal Assessment Scale (VAS), the Female Sexual Function Index (FSFI), the Female Sexual Distress Scare Revised (FSDS-R), the Urinary Distress Inventory (UDI), and adverse events were collected and reported for the two-year follow-up. The changes in scores were compared between the four-week and two-year and the one-year and two-year follow-ups using paired t-tests.

Results

In total, 67 BC survivors were enrolled, 59 completed treatments and the four week follow-up, 39 participated in the one-year follow-up, and 33 participated in the two-year follow-up. After initial improvement in the VAS from baseline to the four week follow-up, there was no statistically significant difference in the VAS score (mean Δ 0.23; 95% CI [-0.05, 0.51], $p = 0.150$) between the four week follow-up and the two-year follow-up. At the two-year follow-up, the FSFI and FSDS-R scores remained improved from baseline and there was no statistically significant change in the FSFI score (mean Δ -0.83; 95% CI [-3.07, 2.38] $p = 0.794$) or the FSDS-R score (mean Δ -2.85; 95% CI [-1.88, 7.59] $p = 0.227$) from the one to two-year follow-up. The UDI scores approached baseline at the two-year follow-up; however, the change between the one- and two-year follow-ups was not statistically significant (mean Δ 4.76; 95% CI [-1.89, 11.41], $p = 0.15$).

Conclusion

Breast cancer survivors treated with fractional CO₂ laser therapy have sustained improvement in sexual function two years after treatment completion, suggesting potential long-term benefit.

CO₂-Laser therapy and Genitourinary Syndrome of Menopause: A Systematic Review and Meta-Analysis

Filippini M¹, Porcari I², Ruffolo AF³, Casiraghi A³, Farinelli M¹, Uccella S², Franchi M², Candiani M³, Salvatore S³

1: Hospital State of Republic of San Marino, San Marino - Republic of San Marino. 2: University of Verona, Verona - Italy. 3: San Raffaele Scientific Institute, University Vita and Salute, Milan - Italy.



Abstract

Objectives

Review of the current literature on CO₂-Laser therapy efficacy for the treatment of GSM.

Materials and Methods

MEDLINE and Embase databases were systematically queried in December 2020. Studies included women with a diagnosis of Vulvo-Vaginal Atrophy (VVA) or GSM without an history of gynaecological and/or breast cancer, pelvic organ prolapse staged higher than 2, pelvic radiotherapy or Sjogren's Syndrome. The quality of the evidence was assessed with the Cochrane risk of bias tool. This study is registered on PROSPERO, number CRD42021238121.

Results

All studies showed a significant reduction in VVA and/or GSM symptoms (dryness, dyspareunia, itching, burning, dysuria). The pooled mean differences for the symptoms were: dryness -5.15 (95% CI:-5.72,-4.58; P < .001; I²:62%; n = 296), dyspareunia -5.27 (95% CI:-5.93,-4.62; P < .001; I²:68%; n = 296), itching -2.75 (95% CI:-4.0,-1.51; P < .001; I²:93%; n = 281), burning -2.66 (95% CI:-3.75,-1.57; P < .001; I²:86%; n = 296) and dysuria -2.14 (95% CI:-3.41,-0.87; P < .001; I²:95%; n = 281). FSFI, WHIS and VMV scores also improved significantly. The pooled mean differences for these scores were: FSFI 10.8 (95% CI:8.41,13.37; P < .001; I²:84%; n = 273), WHIS 8.29 (95% CI:6.16,10.42; P < .001; I²:95%; n = 262) and VMV 30.4 (95% CI:22.38,38.55; P < .001; I²:24%; n = 68). CO₂-Laser application showed a beneficial safety profile and no major adverse events were reported.

Conclusion

The data suggest that CO₂-Laser is a safe energy-based therapeutic option for the management of VVA and/or GSM symptoms in postmenopausal women.

Fractional CO₂ laser for vulvo-vaginal atrophy in gynecologic cancer patients: A valid therapeutic choice? A systematic review

D'Oria O¹, Giannini A¹, Buzzaccarini G², Tinelli A³,
Corrado G⁴, Frega A⁵, Vizza E⁶, Caserta D⁵

1: Sapienza University, Rome - Italy. 2: Gynaecological Clinic, University of Padua, Padua - Italy.
3: Vito Fazzi Hospital, Lecce - Italy. 4: Fondazione Policlinico Universitario A. Gemelli IRCCS, Rome - Italy.
5: Sant'Andrea University Hospital, Sapienza University of Rome, Rome - Italy.
6: IRCCS-Regina Elena National Cancer Unit Institute, Rome, Italy.



Abstract

Introduction

One of the most common adverse events reported by gynecological cancer survivors with spontaneous or iatrogenic menopause is vulvo-vaginal atrophy (VVA). An increasing number of women have this kind of discomfort related to the menopause induced by different cancer therapies. In this regard, fractional CO₂ laser may be a valid therapeutic choice for these patients.

Methods

We performed a literature search of PubMed, EMBASE, SCOPUS and Web of Science databases with search terms of laser CO₂ treatment of vulvovaginal atrophy and gynecologic cancer survivors and reviewed major US Society Guidelines to create this narrative review of this topic. Breast, ovarian endometrial and cervical cancers were included.

Results

Nine studies were included. Fractional CO₂ laser improves clinical symptoms and sexual function, in terms of VHI (vaginal health index) and FSFI (female sexual function index). Non severe adverse event occurred.

Conclusions

According to the best evidence available, fractional CO₂ laser treatment for VVA is an effective and safe therapeutic option for gynecological cancer survivors, improving sexual life and quality of life (QoL).

Keywords

CO₂ laser; Cancer survivors; Menopause; Quality of life; Vulvo-vaginal atrophy.

JAMA Network open - Epub September 21, 2022

Comparison of Severity of Genitourinary Syndrome of Menopause Symptoms After Carbon Dioxide Laser vs Vaginal Estrogen Therapy: A Systematic Review and Meta-analysis

Jang YC¹, Leung CY², Huang HL²

1: Wan Fang Hospital, Taipei Medical University, Taipei City - Taiwan.
2: Graduate School of Medicine, The University of Tokyo, Tokyo - Japan.



Abstract

Importance

Vaginal estrogen for genitourinary syndrome of menopause (GSM) should be used with caution in women with contraindications, highlighting the need for effective treatment alternatives.

Objective

To compare the severity of GSM after vaginal laser vs estrogen therapy.

Data Sources

The PubMed, Embase, and Cochrane Library databases were searched for articles published from database inception to April 8, 2022, with no language restrictions. Reference lists were also searched.

Study Selection

Randomized clinical trials (RCTs) that compared the use of lasers with vaginal estrogen in adults were selected.

Data Extraction and Synthesis

Two investigators independently extracted data from included studies. The Cochrane risk of bias tool for RCTs was used to assess risk of bias of each study. A random-effects model was used to pool mean differences (MDs) with 95% CIs.

Main Outcomes and Measures

Primary outcomes were Vaginal Analog Scale (VAS; higher scores indicate severer symptoms), Vaginal Health Index (VHI; higher scores indicate better vaginal health), Vaginal Maturation Index (VMI; higher scores indicate higher estrogen effect on the vaginal epithelium), Female Sexual Function Index (FSFI; higher scores indicate better female sexual function), and Sexual Quotient–Female (SQ-F; higher scores indicate better female sexual function) questionnaire scores. Urinary symptoms were assessed as an additional outcome. Data analyses were performed from April 9 to 12, 2022.

Results

A total of 6 RCTs with 270 women with GSM were included (135 were randomized to laser therapy and 135 to estrogen therapy; mean age ranged from 54.6 to 61.0 years). No significant differences were found between carbon dioxide laser and vaginal estrogen from baseline to the end of follow-up in overall VAS scores (MD, -0.16 ; 95% CI, -0.67 to 0.36 ; I², 33.31%), VHI (MD, 0.20 ; 95% CI, -0.56 to 0.97 ; I², 83.25%), VMI (MD, -0.56 ; 95% CI, -1.14 to 0.02 ; I², 35.07%), FSFI (MD, -0.04 ; 95% CI, -0.45 to 0.36 ; I², 41.60%), and SQ-F ($P = .37$ based on 1 study). Other questionnaire-based outcome measures demonstrated no difference between groups from baseline to the end of follow-up for changes in urinary symptoms.

Conclusions and Relevance

This systematic review and meta-analysis of RCTs found that vaginal laser treatment is associated with similar improvement in genitourinary symptoms as vaginal estrogen therapy. Further research is needed to test whether vaginal laser therapy could be a potential treatment option for women with contraindications to vaginal estrogen.

PRESENTATIONS & POSTERS

An assessment of the safety and efficacy of the SmartXide² V²LR CO₂ laser for the treatment of vulvovaginal atrophy.

Sokol E.R., Karram M.

[Poster presented at North American Menopause Society (NAMS) 2015, Annual Meeting - Las Vegas, NE, USA.]

Microablative fractional CO₂ laser for vulvovaginal atrophy in women with a history of breast cancer.

Leone Roberti Maggiore U., Parma M., Candiani M., Salvatore S. Journal of Minimally Invasive Gynecology. 2015 Nov–Dec; 22(6) Supplement: p. S100. doi:10.1016/j.jmig.2015.08.269.

[Abstracts of the 44th AAGL Global Congress of Minimally Invasive Gynecology 2015 - Las Vegas, NE, USA]

Treatment of coexistent lichen sclerosus and vulvo-vaginal atrophy with fractional CO₂ laser therapy.

Dell J. Lasers Surg. Med. 2016 April; 48(4):433 #LB39. doi: 10.1002/lsm.22526.

[Late-breaking abstracts for the 36th ASLMS 2016 - Annual Conference, Boston, MA, USA]

Is it all just smoke and mirrors?: Vaginal laser therapy and its assessment by tactile imaging.

Van Raalte H., Bhatia N., Egorov V.

[Poster presented at the International Urogynecological Association (IUGA) - 41th Annual Meeting, Cape Town, South Africa, 2016]

An assessment of the safety and fractional CO₂ laser for the treatment of vulvovaginal atrophy.

Lang P., Hussain S., Karram M. *Lasers Surg. Med.* 2016 April; 48(4):433 #LB40. doi: 10.1002/lsm.22526.

[Late-breaking abstracts for the 36th ASLMS 2016 - Annual Conference, Boston, MA, USA]

Fractional CO₂ laser effect on thick connective tissue of the vaginal wall of women with anterior vaginal prolapse: an ex-vivo study.

Salvatore S., Virgilio S., Palmieri S. Girardelli S., Redaelli A., Parma M., Candiani M., Calligaro A. *European Journal of Obstetrics and Gynecology and Reproductive Biology.* 2017 April; Vol. 211:207–8 #18. Doi: <http://dx.doi.org/10.1016/j.ejogrb.2017.01.044>

[Oral Abstracts, 9th EUGA 2016 - Annual Congress, Amsterdam, Netherlands]

Effects of fractional microablative CO₂ laser therapy on sexual function in postmenopausal women and women with a history of breast cancer treated with endocrine therapy.

Gittens, P., Mullen, G. *The Journal Of Urology.* 2017 April; Vol. 197, No. 4S, Supplement, Page e883. Doi: <https://doi.org/10.1016/j.juro.2017.02.2065>

[Oral communication, AUA 2017 – Annual Meeting, Boston, MA, USA and also presented as poster at the ISSWSH 2017 - Annual Meeting, Atlanta, GA, USA]

Improvement in female sexual function using CO₂ laser therapy.

Sophocles M., Sadiq F. *The Journal of Sexual Medicine.* 2017 May. Volume 14, Issue 5, Supplement 4, 2017, e253-e254 [23rd Congress of the World Association for Sexual Health 2017 - Prague, Czech Republic]

Improvement in female sexual function using CO₂ laser therapy.

Sophocles M. The Journal of Sexual Medicine. 2017 June. Volume 14, Issue 6, Supplement 5, e362-e363, #035. Doi: <https://doi.org/10.1016/j.jsxm.2017.04.039>

[Proceedings of the ISSWSH 2017 - Annual Meeting, Atlanta, GA, USA]

Vaginal microbiota in postmenopausal women treated with pulsed CO₂ laser for genitourinary syndrome of menopause (GSM).

Salvatore S., Verri ., Girardelli S., Iachini E., Mancini N., Marotta E., Candiani M. Maturitas. 2017 June. Volume 100, p:198 #P159. DOI: <https://doi.org/10.1016/j.maturitas.2017.03.259>.

[11th Congress of EMAS 2017 - Amsterdam, Netherlands]

Comparison of vaginal laser therapy to vaginal estrogen therapy (VeLVET) for women with genitourinary syndrome of menopause (GSM).

Paraiso M.F.R., Ferrando C.A., Karram M.M., Sokol E.R., Rardin C.R., Matthews C.A., Iglesia C.B.

[Short Oral 62 at PFD Week 2018 by AUGS - 39th Annual Scientific Meeting October 9-13, 2018. Chicago, IL, USA]

DEKA
Innate Ability

www.dekalaser.com